



Int J Trichology. 2012 Oct-Dec; 4(4): 236–245.

PMCID: PMC3681103

doi: [10.4103/0974-7753.111199](https://doi.org/10.4103/0974-7753.111199)

Topical Melatonin for Treatment of Androgenetic Alopecia

[Tobias W Fischer](#), [Ralph M Trüeb](#),¹ [Gabriella Hänggi](#),² [Marcello Innocenti](#),³ and [Peter Elsner](#)⁴

Department for Dermatology, Allergology and Venereology, University of Lübeck, Lübeck, Germany

¹Center for Dermatology and Hair Diseases, Wallisellen/Zurich, Switzerland

²Center for Dermatology and Hair Diseases, Thalwil, Switzerland

³European Dermatology Institute, Milan, Italy

⁴Department for Dermatology, Clinic for Skin Diseases, Jena University Hospital, Jena, Germany

Address for correspondence: Dr. Tobias W. Fischer, Department of Dermatology, Clinic for Dermatology, Allergology and Venereology, University of Lübeck, Ratzeburger Allee 160, 23538 Lübeck, Germany. E-mail: Tobias.fischer@uk-sh.de

Copyright : © International Journal of Trichology

This is an open-access article distributed under the terms of the Creative Commons Attribution-Noncommercial-Share Alike 3.0 Unported, which permits unrestricted use, distribution, and reproduction in any medium, provided the original work is properly cited.

Abstract

Background:

In the search for alternative agents to oral finasteride and topical minoxidil for the treatment of androgenetic alopecia (AGA), melatonin, a potent antioxidant and growth modulator, was identified as a promising candidate based on *in vitro* and *in vivo* studies.

Materials and Methods:

One pharmacodynamic study on topical application of melatonin and four clinical pre-post studies were performed in patients with androgenetic alopecia or general hair loss and evaluated by standardised questionnaires, TrichoScan, 60-second hair count test and hair pull test.

Results:

Five clinical studies showed positive effects of a topical melatonin solution in the treatment of AGA in men and women while showing good tolerability: (1) Pharmacodynamics under once-daily topical application in the evening showed no significant influence on endogenous serum melatonin levels. (2) An observational study involving 30 men and women showed a significant reduction in the degree of severity of alopecia after 30 and 90 days ($P < 0.001$) based on questionnaires completed by investigators and patients. (3) Using a digital software-supported epiluminescence technique (TrichoScan) in 35 men with AGA, after 3 and 6 months in 54.8% to 58.1% of the patients a significant increase of hair density of 29% and 41%, respectively was measured (M0: 123/cm²; M3: 159/cm²; M6: 173/cm²; ($P < 0.001$)). (4) In 60 men and women with hair loss, a significant reduction in hair loss was observed in women, while hair loss in men remained constant ($P < 0.001$). (5) In a large, 3-month, multi-center study with more than 1800 volunteers at 200 centers, the percentage of patients with a 2- to 3-fold positive hair-pull test decreased from 61.6% to 7.8%, while the percentage of patients with a negative hair-pull test increased from 12.2% to 61.5% ($P < 0.001$). In addition, a decrease in seborrhea and seborrheic dermatitis of the scalp was observed.

Conclusions:

Since safety and tolerability in all of the studies was good, the topical application of a cosmetic melatonin solution can be considered as a treatment option in androgenetic alopecia.

Keywords: Androgenetic alopecia, melatonin, seborrhea, seborrheic dermatitis

INTRODUCTION

Having a full head of hair represents physical attractiveness and youthfulness to men and women, which is why hair loss can have significant negative impacts on the self-esteem and quality of life of those affected. [1,2] By far the most common cause of hair loss in men and women is androgenetic alopecia (AGA), which is a genetically determined, age-dependent, progressive hair-loss condition with gender-specific differences in frequency and severity. [2,3] AGA prevalence among men aged 18 to 29 years is approximately 12% and approximately 50% among men between the ages of 40 and 49 years. [4] Among women, AGA affects approximately 17% of women between the ages of 30 and 49, while postmenopausal prevalence increases significantly and can affect 23-25% of women aged 50 to 69 years. [4] In men, AGA typically begins with a receding hairline and progresses as the hairline continues to recede above the forehead accompanied by a balding pattern on the crown of the head. As the condition progresses, the bald areas can become larger until the top of the head is completely bald with only a fringe of hair remaining at the back of the head and at the temples. [5,6] AGA usually progresses more slowly in women than in men and is accompanied by a gradual, diffuse thinning of the hair on the top of the head with preservation of the hairline along the forehead. [7]

Only two therapeutic agents have been approved to date by the Federal Drug Administration (FDA) and European Medicines Agency (EMA) for treatment of AGA: Oral finasteride (for men) and topical minoxidil (for women and men). [4] Since the active ingredients in these substances have limited efficacy and can involve adverse effects, which compel patients to discontinue the treatment (e.g., rarely gynecomastia in the case of finasteride, [8] and frequently hypertrichosis in the case of minoxidil [9]), it seems appropriate to identify alternative active substances for the treatment of AGA.

According to our current pathogenetic understanding of the condition, AGA is related to genetic peculiarities of androgen metabolism as they relate to the hair follicle. The most significant factor in men is elevated activity of Type II 5-alpha reductase enzymes, which metabolize testicular testosterone circulating in the blood into dihydrotestosterone (DHT) in the genetically predisposed hair follicles of the temporal and vertex regions. [2,3] In women, decreased aromatase activity, which converts ovarian testosterone circulating in the blood into 17 beta-estradiol, tends to play a greater role. [3] An increase in the local concentration of DHT, which binds to the highly expressed androgen receptors in predisposed hair follicles, [2,4] results in a progressive shortening of the anagen phase in favor of a longer telogen phase, which is accompanied by a progressive miniaturization of the hair follicles. This results in the gradual replacement of thick, pigmented terminal hairs with fine, non-pigmented vellus hairs (miniaturized hairs). [10]

In addition to androgen-dependent changes in the morphology and growth dynamics of hair follicles, the pathogenesis of AGA also appears to involve follicular microinflammation and fibrosis, [11] which may be triggered by resident microbial flora in the case of seborrhea, toxins and oxidative stress. [12] Other factors include the aging process, ultraviolet radiation, [13,14] smoking, [15,16] and environmental pollutants. [17] These stressful influences lead to the formation of free radicals, which are no longer able to be sufficiently scavenged by the cell's defense mechanisms, resulting in damage to the hair follicles. [10,12] It was recently proven that the papillary fibroblasts exhibit increased sensitivity to oxidative stress in cases of AGA. [18]

Melatonin (N-acetyl-5-methoxy-tryptamine) is a possible candidate to counteract the oxidative stress associated with general hair loss as well as AGA because of the strong anti-oxidant properties that have been described for this substance. [19] Originally discovered as a neurohormone formed and released by the pineal gland with a circadian rhythm, [20] melatonin regulates a variety of physiological processes, such as seasonal biorhythms and daily sleep-wake cycles, and influences the aging process. [21,22,23] However, melatonin is most notable for its protective and anti-apoptotic effects, which can ensure the functional integrity of non-neoplastic cells, due to its strong anti-oxidant properties and ability to actively capture free radicals. [24,25,26,27,28]

According to recent findings, numerous peripheral organs are not only the target of melatonin bioactivity, but are also simultaneously the site for extrapineal melatonin synthesis, regulation and metabolism of melatonin. Human skin has been shown to have a melatonergic enzyme system, which completely expresses the specific enzymes necessary for melatonin biosynthesis. [29] In addition, keratinocytes, melanocytes, and fibroblasts feature functional melatonin receptors, which are involved in phenotypic effects, such as cellular

proliferation and differentiation.[30] An active melatonergic anti-oxidative system has been identified in the skin, which protects against damage caused by ultraviolet (UV) rays.[31]

Like human skin, human hair follicles have been shown to synthesize melatonin and express melatonin receptors, and an influence on hair growth cycles has been observed.[32,33,34] In human anagen hair follicles cultivated *in vitro* at a concentration of 30 μ M melatonin results in a significantly faster rate of hair follicle growth in comparison to the culture medium alone or even at significantly higher millimole concentrations (1-5 mM).[35] A receptor-mediated mechanism of action involving melatonin seems very likely because stimulation of the hair follicles can be suppressed by the potent melatonin antagonist, 4-phenyl-2-propionamidotetralin.[35] The regulation of melatonin receptors during the course of the hair cycle phases has already been shown, at least in the mouse model.[34] These preclinical data on melatonin-mediated hair growth stimulation are supported by the results from a double-blind, placebo-controlled pilot study, in which topical treatment with 1 ml of a 0.1% melatonin-alcohol solution in women with AGA and diffuse alopecia resulted in a significant increase in detectable anagen hairs in the occipital and frontal areas after six months compared with placebo.[36]

MATERIALS AND METHODS

Development of a pharmacological formula

Based on the positive effects of melatonin on hair growth, ASATONA AG (Zug, Switzerland) developed a topically applied cosmetic hair solution with a melatonin content of 0.0033%, which was intended to slow the hair's aging process and be used as an adjuvant treatment for AGA. In addition to melatonin, this formulation also included ginkgo biloba, which also has pronounced anti-oxidative properties and a positive impact on hair growth by providing the hair roots with better nutrients, as well as biotin, which is an important micronutrient to support cellular functions.

Implementation of the studies

Between January 2003 and October 2006 five studies were performed on behalf of ASATONA AG using the cosmetic melatonin solution described above; of these, the first study looked at the pharmacokinetics of the melatonin solution and the other four studies evaluated the effect of the melatonin solution on hair loss within various patient groups based on various study parameters. The study parameters and study designs are listed together with the results from the individual studies for the purposes of better organization. The studies were named as follows: MEL-COS-1 (Study 1), MEL-COS-AS01 (Study 2), MEL-COS-AS03 (Study 3), MEL-COS-AS04 (Study 4), and MEL-COS-AS05 (Study 5).

RESULTS

Pharmacokinetics of the cosmetic melatonin solution (Study 1; MEL-COS-1)

In order to assess the biological and clinical tolerability of the cosmetic melatonin solution (0.0033%) the pharmacokinetic parameters of the cosmetic hair solution, which was applied once daily to the scalp before going to bed, were analyzed in a double-blind, placebo-controlled cross-over study on four fertile and four postmenopausal healthy women.[37] The study was conducted from January 2003 to April 2003 at the Forenap Centre Hospitalier in Rouffach, France, following review and approval by the corresponding Ethics Committee. Patients received an orientation based on written materials and signed an informed consent form prior to being enrolled. On Day 14 of the study blood samples were collected at 30-min intervals for 8 h following application and at 10, 12, 16 and 20 h following application in order to determine the pharmacokinetics of melatonin. The analysis of the blood samples revealed that repeated application of the cosmetic melatonin solution had no negative influence with respect to an increase or reduction in physiological endogenous melatonin secretion. The mean serum melatonin level over 20 h was similar to the serum level with placebo; the maximum serum melatonin concentration in the melatonin group was somewhat higher than in the placebo group (83.4 pg/ml vs. 71.2 pg/ml) and was reached somewhat earlier [Figure 1]. It was observed that the mean serum melatonin concentration in the fertile women was considerably higher than in the postmenopausal women. The cumulative amount of 6-hydroxy-melatonin

sulfate, the most important melatonin metabolite and melatonin measurement equivalent, excreted in the urine within 24 h was similar in both groups, whereas the values also showed a considerable variability between individuals in each group. No changes were detected in the vital parameters (blood pressure, heart rate) or the electrocardiogram during treatment with melatonin. Following completion of the two-week treatment period two neurocognitive tests, the “critical flicker fusion” and the “multiple choice reaction time” test, were performed and the results showed that repeated application of the cosmetic melatonin solution had no significant influence on reaction time and cortical arousal in comparison with the placebo solution.

Treatment with the cosmetic melatonin solution was shown to be well tolerated because no significant changes were detected in the various laboratory tests and circulatory system parameters nor were any effects on the central nervous system identified in comparison with placebo. There were only a few adverse reactions during the course of the study, such as moderately severe headache and gastrointestinal problems; their incidence was identical within the melatonin and placebo groups and no causal connection was identified with the use of the study medication.

Effect on early-stage AGA (Study 2; MEL-COS-AS01)

Following clarification of the safety aspects of the cosmetic melatonin solution in the pharmacokinetic study (Study 1; MEL-COS-1) the efficacy of the cosmetic melatonin hair solution to be applied at night was evaluated in an open-label observational study on 15 women with Stage I or II AGA (Ludwig scale)[7] and on 15 men with Stage I or II AGA (Hamilton/Norwood scale)[5,6] aged 18-40 years.[38] The study was carried out from March 2003 to June 2003 at the Instituto Dermatologico Europeo (European Dermatological Institute)(IDE) in Milan, Italy following review and approval by the corresponding Ethics Committee in accordance with Good Clinical Practice (GCP). Prior to participating in the study the patients gave written informed consent. Based on objective examination forms for the medical investigators and subjective questionnaires for the patients a significant reduction in the degree of severity of the alopecia was identified after just 30 days with a further significant drop in the degree of severity after 90 days ($P < 0.001$) [Figure 2]. Out of a maximum of 3 points the cosmetic properties “scent”, “consistency”, and “absorption” scored 2.67, 2.52, and 2.57, respectively; out of a maximum of 1 point the effect of the product on the overall greasiness of the hair scored 0.43, while its effect on comb-ability scored 0.76. Out of a maximum of 2 points satisfaction with the product scored 1.80; out of a maximum of 3 points intolerability scored 0.54 after 30 days and 0.52 after 90 days.

TrichoScan study to evaluate efficacy (Study 3; MEL-COS-AS03)

In order to provide a reliable, technically and methodologically objective assessment of the therapeutic benefits of the cosmetic melatonin solution a further open-label, clinically controlled study was carried out based on the TrichoScan method to determine the efficacy and tolerability of the melatonin hair solution, which was applied to the scalp each night by 35 men (aged 18-41 years) with Stage I or II AGA (Hamilton/Norwood scale) for a period of 6 months.[39] The study was carried out from April 2004 to April 2005 at the Instituto Dermatologico Europeo (European Dermatological Institute) (IDE) in Milan, Italy following review and approval by the corresponding Ethics Committee in accordance with GCP. Prior to participating in the study the patients signed a written informed consent form. TrichoScan is a digital software-supported epiluminescence technique for measuring hair count (number of hairs/0.7cm²), hair density (number of hairs/cm²), hair diameter, anagen/telogen ratio, and vellus hair/terminal hair ratio.[40,41] The results of this study showed an increase in the hair count (number of hairs/0.7cm²) in 54.8% of participants after 3 and 6 months, respectively, and improved hair density (number of hairs/cm²) in 54.8% and 58.1% of participants after 3 and 6 months, respectively.

The increase in the hair count was 29.2% (3 months vs. 0 month) and 42.7% (6 months vs. 0 month); both values were statistically significant ($P < 0.001$) (Month 0: 85.76 ± 27.0; Month 3: 110.82 ± 31.7; Month 6: 122.35 ± 40.5). In the case of hair density an increase of 29.1% and 40.9% was determined after 3 and 6 months, respectively (Month 0: 123.15 ± 39.0; Month 3: 159.03 ± 46.8; Month 6: 173.56 ± 58). The differences among the hair density values were also significant ($P < 0.001$).

Objective assessment of treatment with the cosmetic melatonin solution by the medical investigator at each

visit found improved hair loss in 26.6% (Day 30), 48.2% (Day 90) and 32.1% (Day 180) of patients, whereby the proportion of patients showing improvement was greatest after 90 days and even included a small group of patients with new hair growth. In addition, the proportion of patients exhibiting no change in hair loss during the period from Day 30 to Day 90 decreased from about 73.3% to 48.2% and this value was maintained through Day 180. Hair loss continued in 3.4% of patients (at 90 days) and in 19.3% (at 180 days) [Figure 3].

Based on the subjective patient questionnaires, 30%, 34.5% and 29% of patients were satisfied with the treatment after a treatment duration of 30, 90 and 180 days, respectively, while 70%, 58.6% and 58.0%, respectively, were mostly satisfied; conversely, the proportion of patients who were dissatisfied with treatment was relatively small over the course of the study with 0% (at 30 days), 6.8% (at 90 days) and 12.9% (at 180 days). The patient questionnaire also included an evaluation of cosmetic characteristics, such as scent, consistency, absorption, greasiness, and combability following use of the product.

The scent was described by 83.8% of patients as above average and by 6.4% of patients as excellent, while 9.6% were dissatisfied with the scent. The consistency was described by 77.4% as above average, by 9.6% as excellent, and by 12.9% as below average. The absorption of the product into the scalp was considered to be above average by 80.6%, excellent by 12.9%, and poor by 6.4%. Ninety-three percent of patients observed no greasiness of the scalp following application and combability was classified as above average by 96.7%. Only one patient reported occasional itchiness following application of the product. Overall, 93.5% of patients classified the cosmetic melatonin solution as above average (80.6%) or excellent (12.9%).

Comb test at hair salons (Study 4; MEL-COS-AS04)

The efficacy of the cosmetic melatonin solution was evaluated at four hair salons within the framework of an open-label observational study, which included 40 male and 20 female patients (mean age 41 years) with early-stage hair loss or hair-thinning, who applied the melatonin hair solution each evening for 90 days.[42] The study was conducted as an open-label, “non-FDA-related” cosmetic study at 4 hair salons in Tampa, FL, USA from June 2005 to September 2005. Prior to participating in the study the patients given written informed consent. Based on a 4-point scale the hair stylists reported an improvement in hair texture during treatment with the cosmetic melatonin hair solution, which achieved a statistically significant level in both the female as well as the male patients ($P = 0.002$ and $P = 8 * 10^{-5}$, respectively). In addition, the hair stylists identified a reduction in hair loss, which was also statistically significant among both women and men ($P = 4 * 10^{-6}$ and $P = 3 * 10^{-5}$, respectively) [Table 1]. Mean hair loss, as determined by the patients during a timed 60-second hair count test performed while combing their hair each morning,[43] fell significantly among women during the first 40 days and continued to drop significantly during the next 40 days, while mean hair loss in men remained almost constant throughout the course of the study, though it was considerably lower than the mean value for women. With respect to satisfaction with the treatment, the entire group exhibited a trend toward improvement, whereby satisfaction among women increased significantly ($P = 0.002$) and remained almost constant among the men [Table 1]. Four patients experienced mild side effects during the course of the study, including temporary reddening, sensitivity, itching or burning. However, none of these patients discontinued the study.

Multicenter study proves efficacy (Study 5; MEL-COS-AS05)

A large, open-label, multi-center study, which included 901 men (47.6%) with stage I or II AGA (Hamilton scale) and 990 women (52.4%) with stage I or II AGA (Ludwig scale), all of whom applied a cosmetic hair solution containing melatonin each evening for 90 days, was carried out at 200 dermatology centers and practices in order to provide a comprehensive assessment of the therapeutic benefits of the cosmetic melatonin solution.[44] The study was carried out from March 2004 to October 2006 under the guidance of the Instituto Dermatologico Europeo [European Dermatological Institute] (IDE) in Milan, Italy following review and approval by the corresponding Ethics Committee in accordance with GCP. Prior to participating in the study the patients gave written informed consent.

Clinical response was evaluated based on hair pull tests, a semi-quantitative method for the assessment of hair-loss activity.[4,45] Each hair pull test was classified as positive based on three levels (+, ++, +++) or

negative (-). Over the course of the study the results from the tests performed by the medical investigators at Day 30 and Day 90 revealed a significant decrease—from 61.6% to 33.7% (after 30 days) and 7.8% (after 90 days)—in the proportion of patients with severe and moderately severe hair loss ($P < 0.001$). In addition, the proportion of patients in whom no hair loss was identified, rose significantly from 12.2% to 25.5% (after 30 days) and 61.5% (after 90 days) during treatment with the cosmetic melatonin solution ($P < 0.001$; Student's *t*-test) [Figure 4](#).

According to the objective assessment of the medical investigators, treatment with the cosmetic melatonin solution resulted in significantly improved hair loss in 59.4% and 66.4% of patients after 30 and 90 days, respectively ($P < 0.001$), while new hair growth was identified in 4.5% and 22.5% of patients at the same respective intervals ($P < 0.001$) [[Figure 5](#)].

According to the subjective self-assessment performed by the patients, the proportion of patients suffering from mild or severe hair loss rose initially after 30 days from 71.4% to 82.0%, but then dropped significantly to 60.0% after 90 days. Consequently, the proportion of patients reporting no hair loss dropped from 27.7% to 18% after 30 days, but then rose considerably to 40% after 90 days [[Figure 6](#)].

In addition to a reduction in hair loss, treatment with the melatonin solution also improved seborrhea. The proportion of patients with moderately severe or severe seborrhea was initially 35.7% and dropped to 18% and 5.4% after 30 and 90 days, respectively. Meanwhile, the correspondingly significant increase in the proportion of patients reporting no seborrhea went from 32.5% (at baseline) to 45.4% (after 30 days) and 67.6% (after 90 days) ($P < 0.001$) [[Figure 7](#)].

The presence of seborrheic dermatitis was included as another study parameter. At the start of the study the proportion of patients with seborrheic dermatitis was 34.5%; this value dropped to 22.4% and 9.9% following application of the cosmetic melatonin solution for 30 days and 90 days, respectively. Consequently, the proportion of patients reporting no seborrheic dermatitis increased from 65.5% to 77.6% and 90.1% at the same respective intervals [[Figure 8](#)].

A majority of the patients (74.4%) was satisfied with the cosmetic results following 90 days of treatment, while 23.3% were moderately satisfied, and a small proportion (2.3%) was dissatisfied with the results. Based on the assessments by the medical investigators and the patients, treatment with the cosmetic melatonin hair solution was considered to be well tolerated by a majority of investigators (88.0%) and users (82.7%), while both the investigators as well as the patients classified the treatment as poorly tolerated in only 2.0% and 3.0% of the cases, respectively. According to the overall assessment by the medical investigators and the patients, the melatonin solution was found to be more highly effective in improving hair loss than other previously used products in 85.3% and 80.8% of cases, respectively, while only 0.7% of the medical investigators and 1.0% of the patients found the cosmetic hair solution to be less effective than other previously used products.

DISCUSSION

It is known based on *in vitro* testing in the hair organ culture model that the neurohormone melatonin is able to stimulate growth in human hair follicles.[[35](#)] On the basis of five clinical studies referred to, this paper examined whether the results from the *in vitro* data could be confirmed under *in vivo* clinical conditions.

The first study on pharmacodynamics and tolerability found a slightly elevated, yet not significantly different serum melatonin level following topical application of a 0.0033% melatonin solution as compared with a melatonin-free placebo solution.[[37](#)] The cumulative amount of the melatonin metabolite 6-hydroxymelatonin, which provides an indirect indication of serum melatonin levels, was comparable in both groups. Neurocognitive changes and effects on vital signs were not observed.

In the second study involving 30 patients with early-stage AGA, melatonin achieved a significant reduction in hair loss after 30 and 90 days. In evaluating the study it must be borne in mind that the value of the results is limited because they are not based on objective image-supported measuring methods but instead on objective examination forms for the medical investigators and subjective questionnaires for the patients; in addition, the observed effect was not placebo-controlled. Nevertheless, it should be noted that a significant

before-and-after effect was observed.[38] Tolerability was relatively good (18% of cases reported intolerability) and acceptance of the product was high at 90%.

The third study, an open-label, clinically controlled study involving 35 men with AGA, demonstrated that 6 months of topical melatonin treatment resulted in a significant increase in hair density in 54.8% and 58.1% of the men after 3 and 6 months, respectively; these results were observed using TrichoScan, an objective, digital software-supported epiluminescence technique.[40,41] The hair density value was + 29% (after 3 months) and + 41% (after 6 months).[39] The assessment by the medical investigators also found an improvement in hair loss (27% to 48%; Month 1 and 3). A stabilization of hair loss was observed in 75% of the patients at Month 1 and in 50% at Month 3 and 6, respectively. The cosmetic characteristics of the hair treatment were considered relatively good and tolerability was also good in all but one of the 35 study participants.

In the fourth study, an observational study involving four hair salons and 60 male and female patients with early-stage hair loss, hair stylists performed a before-and-after comparison of hair texture and hair loss based on a 4- and 5-point scale, respectively; in this study the hair texture was found to have significantly improved and hair loss was found to have significantly decreased. Based on a standardized combing test (60-second hair count test)[43] the female patients demonstrated a significant reduction in hair loss, while hair loss in men remained constant, but at a low level.[42] Side-effects included temporary reddening, sensitivity, itching or burning, none of which resulted in discontinuation of the study.

Finally, in the fifth study, a 3-month, large-scale, open-label, multi-center study involving 1891 female and male patients with Stage I and II AGA, the proportion of patients with 2- and 3-fold positive hair pull tests dropped from 61.6% at baseline to 7.8% after 3 months, while the proportion with negative hair pull tests (no hair loss) rose from 12.2% to 61.5%.[44] Based on objective standardized examination forms for the medical investigators a reduction in hair loss of up to 66% was able to be identified, while new hair growth was identified in up to 22.5% of patients after 3 months. In addition, the medical investigators observed a reduction in the proportion of patients with severe and moderate seborrhea from 35.7% to 5.4%. This was observed in association with a simultaneous reduction in seborrheic dermatitis from 34.5% to 9.9%. Eighty-eight percent of the medical investigators and 82.7% of the patients classified the tolerability of the melatonin-containing solution as above average, while 2% and 3%, respectively, classified it as poor.

The designs for the studies on the effect of melatonin on AGA and on hair loss, respectively, must be evaluated using different approaches. The first study by Lorenzi and Caputo (Study 2)[38] made exclusive use of examination forms for the medical investigators and questionnaires for the patients; while the examination forms enabled an objective clinical evaluation based on training at least in the case of the medical investigators, they were still subject to higher variability than objective measurement methods. In contrast the second study by Lorenzi (Study 3)[39] used an objective, instrument-based method, the TrichoScan, and included 35 men. The intra-investigator correlation coefficient for the TrichoScan method is reported to be 91% and the intra-investigator correlation coefficient 97%.[41] Thus, the TrichoScan method provides a reliable before-and-after comparison and is highly reproducible during the course of a clinical study.[40,41,46] The increase in the measured hair count from 123 hairs/cm² at baseline to 159 and 173 hairs/cm² after 3 and 6 months, respectively, must be considered clinically relevant. Study 4 was conducted as an observational study including 60 patients, in which significant improvements were identified in the before-and-after comparisons of hair texture and hair loss; however, the study included no placebo group. The 60-second hair count test is a relatively standardized method performed by the patients themselves, in which the patients are required to comb their hair continuously for 60 seconds. The method is easy to perform and reproduces daily hair loss in a standardized manner.[43] The multi-center study (Study 5) with over 1800 participants at 200 centers is the largest study on the use of melatonin in early-stage AGA[44] and in terms of the number of patients it exceeds the large-scale study on the use of finasteride in male AGA with 1500 patients.[47] The semi-quantitative methodology of the pull test is subject to relatively major inter-investigator variability. However, it should be noted that the individual investigators usually achieve a high level of intra-individual standardization.[4,45] While the method is considerably inferior by quality with respect to variance and reproducibility as compared with the TrichoScan method, the blinded hair count

method or global photography evaluation by a blinded panel of investigators, the method still provides results with a certain level of reliability based on intra-individual standardization by the individual investigators. In the case of the multi-center study with 200 centers under consideration here, the high number of centers reduces the influence of inter-investigator variability on the study results to a relatively low level. However, this study was not placebo-controlled either, which still decreases its significance. Nevertheless, the study included two further study parameters, seborrhea and the presence of seborrheic dermatitis, which represent significant negative impacts on patients and which responded well to treatment with melatonin.

The positive effects of melatonin on hair growth in patients with AGA were confirmed by the results from a pilot study on melatonin, which was conducted as a placebo-controlled, randomized, double-blind study on 40 patients with androgenetic and/or diffuse alopecia.[36] Although melatonin's exact mechanism of action in the stimulation of growth in human hair is not yet clearly understood, studies on animals and on *in vitro*[33] animal and human organ culture models with hair follicles offer some clues. Research in the animal sciences especially has shown that melatonin can increase wool and cashmere production and modulate the development and cycle regulation of outer coats, molting, and hair color.[48,49]

Receptor-mediated melatonin effects are theoretically possible because the MT1 membrane receptor has been detected in both human hair follicle keratinocytes and fibroblasts of the dermal hair papillae by means of Real Time Polymerase Chain Reaction (RT-PCR)[30] as well as *in situ* in the human scalp at the center of the outer and inner root sheath of the hair follicle.[28] An aberrant form of the MT2 membrane receptor has also been detected in human fibroblasts of the dermal hair papillae.[30] A specific, hair cycle-dependent expression of MT2 in the skin has been demonstrated in the C57BL/6 mouse model.[34] Thus, this receptor could have a functional influence on the hair cycle if the knowledge gained from the mouse model can be applied to humans. To date only weak expression of MT2 in the human hair follicle has been detected in the inner root sheath using immunohistochemical techniques.[28] While individual human skin cells (keratinocytes, melanocytes, fibroblasts) contain the MT3 receptor or NQO2, it has not been detected to date in individual hair follicle cells or *in situ* in the hair follicle.[27] MT3/NQO2 could play a role in the prevention of oxidative stress in HF catagen regression or in oxidative stress-induced hair aging.[12] The nuclear melatonin receptor ROR α performs a biological function in hair growth because ROR α -knock-out mice had significantly thinner coats.[33] Hair cycle-dependent regulation of the nuclear receptor in the inner and outer root sheath was also able to be identified in C57BL/6 mice.[34] The melatonin receptors identified to date are all in the root sheath of the hair, which assists in the regulation of hair growth in addition to mechanically stabilizing the hair shaft. Thus, it can be inferred that the growth-promoting properties of melatonin are at least partially regulated by its receptors in the root sheath of the hair.

The effect of melatonin on hair growth may also be mediated by interaction with androgens and estrogens as well as their receptors, as evidenced by the antiandrogenic effect of melatonin on benign prostate cells.[50] While the antiandrogenic effect on prostate cells is accompanied by an inhibition of proliferation, antiandrogenic effects on hair follicles include prolongation of the hair cycle and decreased miniaturization.[2] Human benign prostate cells and human skin express functionally active melatonin receptors (MT1), [30,51] making it possible to also assume a melatonin receptor-mediated, antiandrogenic effect in the skin and hair follicles.

Melatonin has also demonstrated a modulating effect on the aromatase activity and gene expression necessary for the formation of estrogen in mammary cancer cell lines.[52] Melatonin performs hair cycle-dependent regulation of α -estrogen receptor gene expression in murine hair follicles.[34] Relevance to human hair follicles will need to be clarified in functional studies.

In summary, it can be stated that multiple studies with different study designs observed mostly positive effects resulting from the topical application of a cosmetic melatonin solution in women and men with early-stage AGA (Phase I and II, Hamilton and Ludwig scales, respectively) or general hair loss with a partial reduction in hair loss, as well as new hair growth in some cases. Although the mechanism of action has not yet been clarified in detail, it appears highly likely that it is based on a melatonin receptor-mediated antiandrogenic effect and/or an antioxidative effect. Due to the fact that the application of the melatonin solution has been shown to be very well tolerated in a total of 5 studies and because positive effects on hair

growth were observed in the before-and-after comparisons, the cosmetic melatonin solution represents a possible option for delaying hair aging, hair loss in general, and for the treatment of early-stage AGA in men and women.

Footnotes

Source of Support: Nil

Conflict of Interest: None declared.

REFERENCES

1. Fischer TW, Schmidt S, Strauss B, Elsner P. A tool for evaluation of disease-specific life quality in hair patients. *Hautarzt*. 2001;52:219–27. [PubMed: 11284067]
2. Trueb RM. Molecular mechanisms of androgenetic alopecia. *Exp Gerontol*. 2002;37:981–90. [PubMed: 12213548]
3. Hoffmann R, Happel R. Current understanding of androgenetic alopecia. Part I: Etiopathogenesis. *Eur J Dermatol*. 2000;10:319–27. [PubMed: 10846263]
4. Fischer TW. Alopecia - Diagnostic and Therapeutic Management. *Akt Dermatol*. 2008;34:209–25.
5. Hamilton JB. Patterned loss of hair in man; types and incidence. *Ann N Y Acad Sci*. 1951;53:708–28. [PubMed: 14819896]
6. Norwood OT. Male-pattern baldness. Classification and incidence. *South Med J*. 1975;68:1359–70. [PubMed: 1188424]
7. Ludwig E. Classification of the types of androgenetic alopecia (common baldness) occurring in the female sex. *Br J Dermatol*. 1977;97:247–54. [PubMed: 921894]
8. Ramot Y, Czarnowicki T, Zlotogorski A. Finasteride induced Gynecomastia: Case report and Review of the Literature. *Int J Trichol*. 2009;1:27–9. [PMCID: PMC2929552]
9. Dawber RP, Rundegren J. Hypertrichosis in females applying minoxidil topical solution and in normal controls. *J Eur Acad Dermatol Venereol*. 2003;17:271–5. [PubMed: 12702063]
10. Trueb RM. Das Haar im Alter. *Haut*. 2008;4:152–5.
11. Mahé YF, Michelet JF, Billoni N, Jarrousse F, Buan B, Commo S, et al. Androgenetic alopecia and microinflammation. *Int J Dermatol*. 2000;39:576–84. [PubMed: 10971723]
12. Trüb RM. Oxidative stress in Ageing of Hair. *Int J Trichol*. 2009;9:6–14. [PMCID: PMC2929555]
13. Camacho F, Moreno JC, Garcia-Hernandez MJ. Telogen alopecia from UV rays. *Arch Dermatol*. 1996;132:1398–9. [PubMed: 8915333]
14. Lu ZF, Fischer TW, Hasse S, Sugawara K, Kamenisch Y, Krengel S, et al. The human hair follicle as a model for exploring the effects of ultraviolet radiation in a complex tissue interaction system in situ. *J Invest Dermatol*. 2009;129:1790–1804. [PubMed: 19158839]
15. Trüb RM. Association between smoking and hair loss: another opportunity for health education against smoking? *Dermatology*. 2003;206:189–91. [PubMed: 12673073]
16. Su LH, Chen TH. Association of androgenetic alopecia with smoking and its prevalence among Asian men: A community-based survey. *Arch Dermatol*. 2007;143:1401–6. [PubMed: 18025364]
17. Srogi K. Mercury content of hair in different populations relative to fish consumption. *Rev Environ Contam Toxicol*. 2007;189:107–30. [PubMed: 17193738]
18. Bahta AW, Farjo B, Philpott MP. Premature senescence of balding dermal papilla cells *in vitro* is associated with p16INK4a expression. *J Invest Dermatol*. 2008;128:1088–94. [PubMed: 17989730]

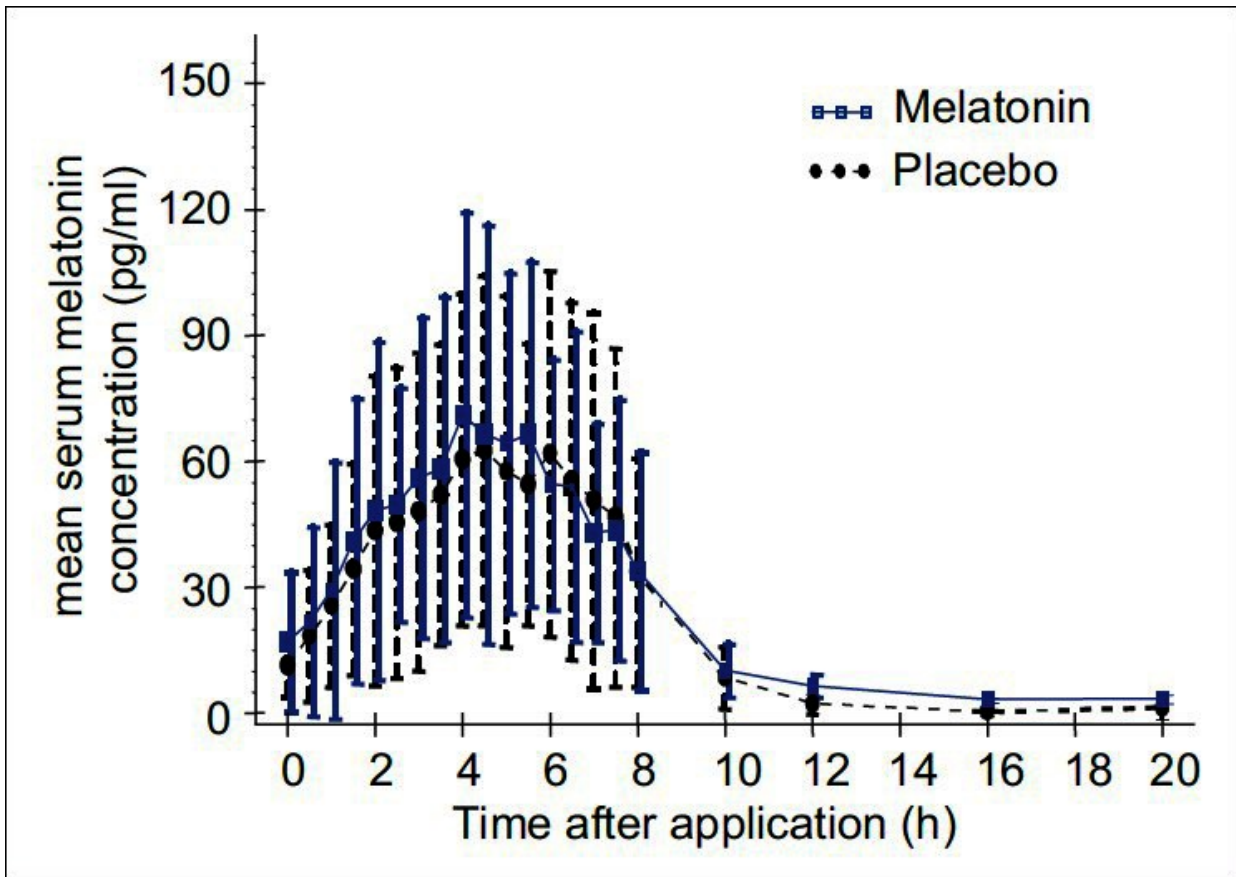
19. Tan DX, Chen LD, Poeggeler B, Manchester LC, Reiter RJ. Melatonin: A potent, endogenous hydroxyl radical scavenger. *Endocr J.* 1993;1:57–60.
20. Lerner AB, Case JD, Takahashi Y. Isolation of melatonin, a pineal factor that lightens melanocytes. *J Am Chem Soc.* 1958;80:2587.
21. Arendt J. Melatonin. *Clin Endocrinol (Oxf)* 1988;29:205–29. [PubMed: 3073883]
22. Lerchl A, Schlatt S. Influence of photoperiod on pineal melatonin synthesis, fur color, body weight, and reproductive function in the female Djungarian hamster, *Phodopus sungorus*. *Neuroendocrinology.* 1993;57:359–64. [PubMed: 7685505]
23. Karasek M, Reiter RJ. Melatonin and aging. *Neuroendocrinol Lett.* 2002;23(Suppl 1):14–6. [PubMed: 12019345]
24. Fischer TW, Scholz G, Knoll B, Hipler UC, Elsner P. Melatonin reduces UV-induced reactive oxygen species in a dose-dependent manner in IL-3-stimulated leukocytes. *J Pineal Res.* 2001;31:39–45. [PubMed: 11485003]
25. Fischer TW, Zmijewski MA, Wortsman J, Slominski A. Melatonin maintains mitochondrial membrane potential and attenuates activation of initiator (casp-9) and effector caspases (casp-3/casp-7) and PARP in UVR-exposed HaCaT keratinocytes. *J Pineal Res.* 2008;44:397–407. [PMCID: PMC2365494] [PubMed: 18086147]
26. Reiter RJ, Tan DX, Poeggeler B, Menendez-Pelaez A, Chen LD, Saarela S. Melatonin as a free radical scavenger: implications for aging and age-related diseases. *Ann N Y Acad Sci.* 1994;719:1–12. [PubMed: 8010585]
27. Slominski A, Fischer TW, Zmijewski MA, Wortsman J, Semak I, Zbytek B, et al. On the role of melatonin in skin physiology and pathology. *Endocrine.* 2005;27:137–48. [PMCID: PMC1317110] [PubMed: 16217127]
28. Slominski A, Wortsman J, Tobin DJ. The cutaneous serotonergic/melatonergic system: Securing a place under the sun. *FASEB J.* 2005;19:176–94. [PubMed: 15677341]
29. Slominski A, Pisarchik A, Semak I, Sweatman T, Wortsman J, Szczesniewski A, et al. Serotonergic and melatonergic systems are fully expressed in human skin. *FASEB J.* 2002;16:896–8. [PubMed: 12039872]
30. Slominski A, Pisarchik A, Zbytek B, Tobin DJ, Kauser S, Wortsman J. Functional activity of serotonergic and melatonergic systems expressed in the skin. *J Cell Physiol.* 2003;196:144–53. [PubMed: 12767050]
31. Fischer TW, Sweatman TW, Semak I, Sayre RM, Wortsman J, Slominski A. Constitutive and UV-induced metabolism of melatonin in keratinocytes and cell-free systems. *FASEB J.* 2006;20:1564–6. [PubMed: 16793870]
32. Fischer TW, Slominski A, Tobin DJ, Paus R. Melatonin and the hair follicle. *J Pineal Res.* 2008;44:1–15. [PubMed: 18078443]
33. Fischer TW. The influence of melatonin on hair physiology. *Hautarzt.* 2009;60:962–72. [PubMed: 19957072]
34. Kobayashi H, Kromminga A, Dunlop TW, Tychsen B, Conrad F, Suzuki N, et al. A role of melatonin in neuroectodermal-mesodermal interactions: The hair follicle synthesizes melatonin and expresses functional melatonin receptors. *FASEB J.* 2005;19:1710–2. [PubMed: 16030176]
35. Fischer TW, Fischer A, Knöll B, Hipler UC, Elsner P. Melatonin in low doses enhances *in vitro* human hair follicle proliferation and inhibits hair growth in high doses. *Arch Derm Res.* 2000;292:147.
36. Fischer TW, Burmeister G, Schmidt HW, Elsner P. Melatonin increases anagen hair rate in women with

androgenetic alopecia or diffuse alopecia: Results of a pilot randomized controlled trial. *Br J Dermatol*. 2004;150:341–5. [PubMed: 14996107]

37. Macher JP. Pharmacokinetics and clinical and biological tolerability of repeated topical application of a melatonin-containing cosmetic hair solution in healthy female volunteers. A double-blind, placebo-controlled, cross-over design study. Clinical Study Report. MEL-COS-1. Data on file. Asatona AG, Switzerland.
38. Lorenzi S, Caputo R. Melatonin cosmetic hair solution: Open study of the efficacy and the safety on hair loss (telogen) control and hair growth (anagen) stimulation. MEL-COS-AS01. Data on file. Asatona AG, Switzerland.
39. Lorenzi S, Barbareschi M, Caputo R. Efficacy and safety of a melatonin-containing cosmetic hair solution in the treatment of early stages of male androgenic alopecia. Open study with Trichoscan evaluation. Report/Protocol. MEL-COS-AS03. Data on file. Asatona AG, Switzerland.
40. Gassmueller J, Rowold E, Frase T, Hughes-Formella B. Validation of TrichoScan technology as a fully-automated tool for evaluation of hair growth parameters. *Eur J Dermatol*. 2009;19:224–31. [PubMed: 19220982]
41. Hoffmann R. TrichoScan: Combining epiluminescence microscopy with digital image analysis for the measurement of hair growth *in vivo*. *Eur J Dermatol*. 2001;11:362–8. [PubMed: 11399546]
42. Schmid HW. Use Test with of a melatonin-containing cosmetic hair solution to determine the change of the appearance and texture of thinning and fine hair following the application. Statistical Report. MEL-COS-AS04. Data on file. Asatona AG, Switzerland.
43. Miller JJ, Fang S. Results of 60-second timed hair counts in women between the ages of 20-60 years. *J Am Acad Dermatol*. 2004;50:93.
44. Innocenti M, Barbareschi M. Open-label, non comparative, multicenter clinical study on efficacy and safety of a melatonin-containing cosmetic hair solution in the treatment of hair loss (telogen) and in the stimulation of hair re-growth (anagen) Report. MEL-COS-AS05. Data on file. Asatona AG, Switzerland.
45. Hillmann K, Blume-Peytavi U. Diagnosis of hair disorders. *Semin Cutan Med Surg*. 2009;28:33–8. [PubMed: 19341940]
46. Hoffmann R. Trichoscan: what is new? *Dermatology*. 2005;211:54–62. [PubMed: 15983438]
47. Kaufman KD, Olsen EA, Whiting D, Savin R, DeVillez R, Bergfeld W, et al. Finasteride in the treatment of men with androgenetic alopecia. Finasteride male pattern hair loss study group. *J Am Acad Dermatol*. 1998;39:578–89. [PubMed: 9777765]
48. Ibraheem M, Galbraith H, Scaife J, Ewen S. Growth of secondary hair follicles of the Cashmere goat *in vitro* and their response to prolactin and melatonin. *J Anat*. 1994;185(Pt 1):135–42. [PMCID: PMC1166822] [PubMed: 7559108]
49. Nixon AJ, Ashby MG, Saywell DP, Pearson AJ. Seasonal fiber growth cycles of ferrets (*Mustela putorius furo*) and long-term effects of melatonin treatment. *J Exp Zool*. 1995;272:435–45. [PubMed: 7673877]
50. Alonso R, Prieto L, Hernandez C, Mas M. Antiandrogenic effects of the pineal gland and melatonin in castrated and intact prepubertal male rats. *J Endocrinol*. 1978;79:77–83. [PubMed: 712320]
51. Gilad E, Matzkin H, Zisapel N. Interplay between sex steroids and melatonin in regulation of human benign prostate epithelial cell growth. *J Clin Endocrinol Metab*. 1997;82:2535–41. [PubMed: 9253330]
52. Cos S, González A, Martínez-Campa C, Mediavilla MD, Alonso-González C, Sánchez-Barceló EJ. Estrogen-signaling pathway: A link between breast cancer and melatonin oncostatic actions. *Cancer Detect Prev*. 2006;30:118–28. [PubMed: 16647824]

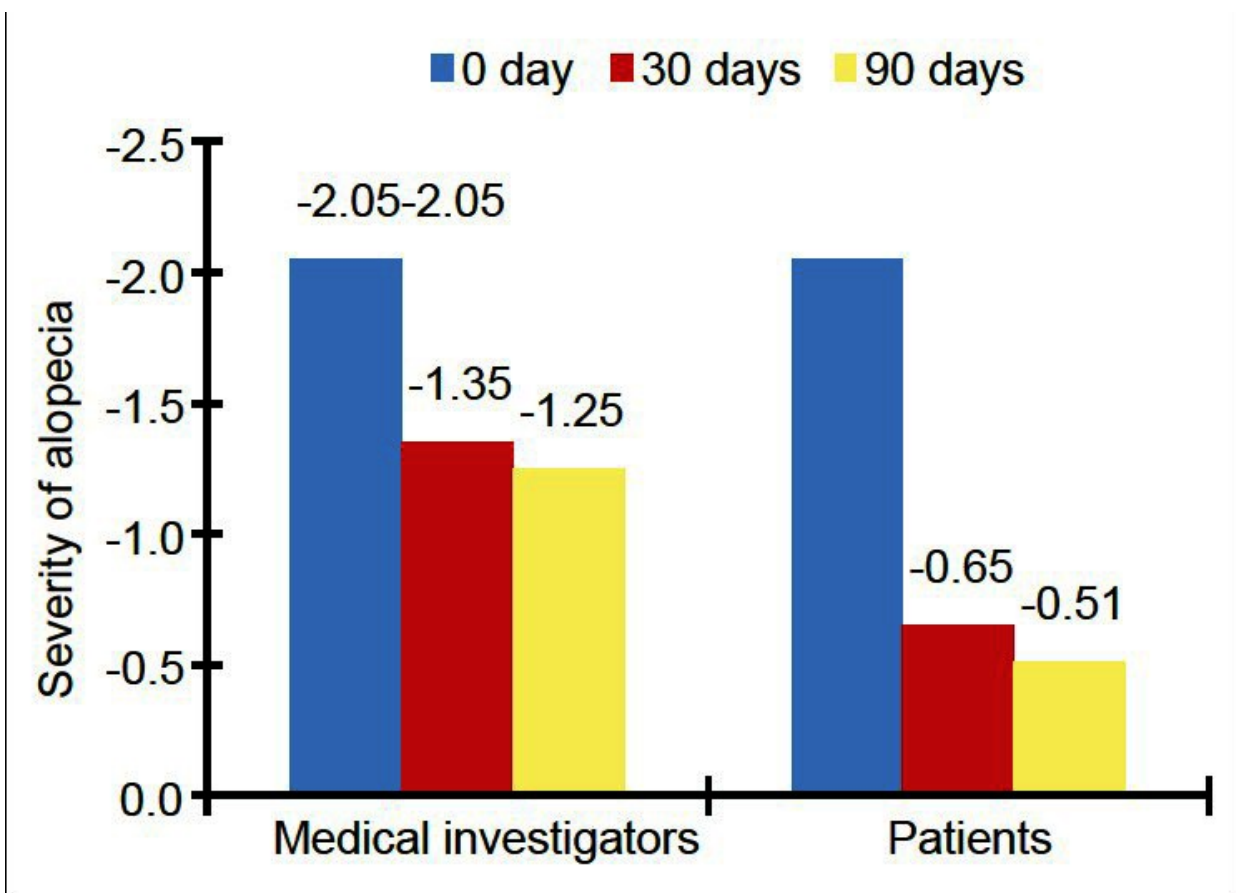
Figures and Tables

Figure 1



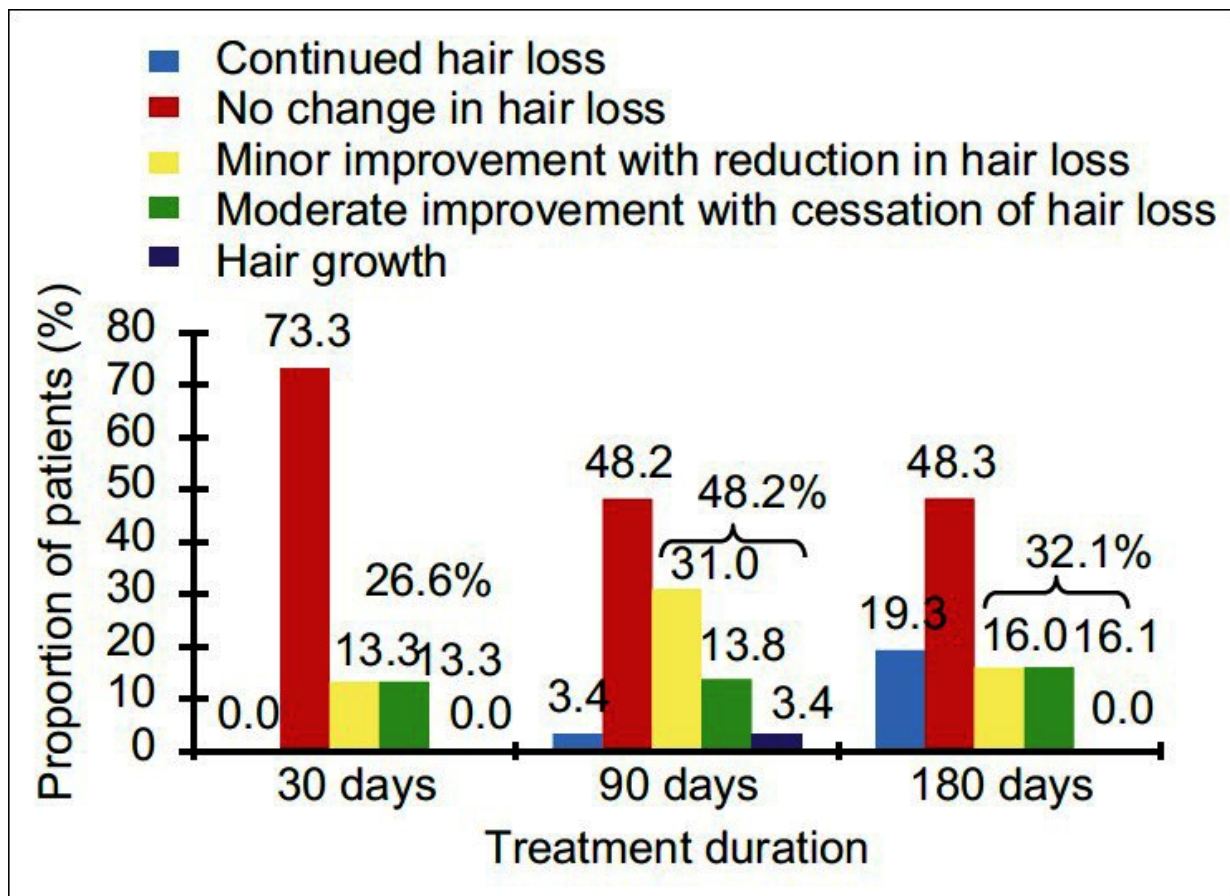
Mean serum concentration after two-week treatment with the cosmetic melatonin solution

Figure 2



Objective and subjective assessment of the severity of the alopecia

Figure 3



Reduction of the hair loss assessed by means of objective questionnaires completed by medical investigators. Percent values above the bracket: Sum of the percent values for “minor improvement with reduction in hair loss”, “moderate improvement with cessation of hair loss” and “hair growth”

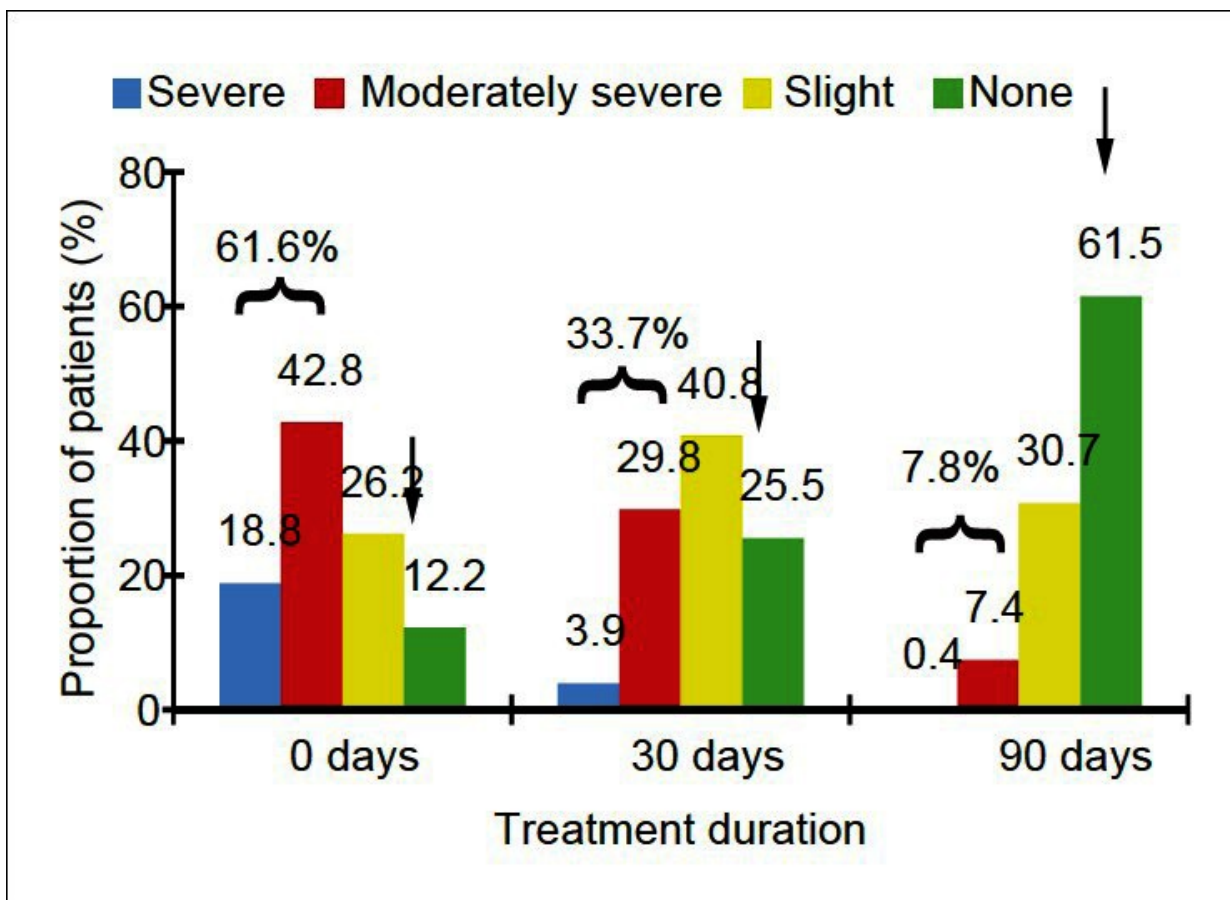
Table 1

	Entire group	Women	Men
Hair texture (4-point scale)	0.74 ($P=7.10^{-9}$)	1.08 ($P=0.002$)	0.58 ($P=8.10^{-5}$)
Hair loss (5-point scale)	0.59 ($P=1.10^{-7}$)	0.69 ($P=4.10^{-6}$)	0.55 ($P=3.10^{-5}$)
Satisfaction (4-point scale)	0.22 ($P=0.045$)	0.46 ($P=0.002$)	0.10 ($P=0.50$)

Difference from the mean value at 60 and 90 days minus value at 30 days. All the values are increases of the values on a 4-point and 5-point scale, respectively; Statistical test: Paired t-test

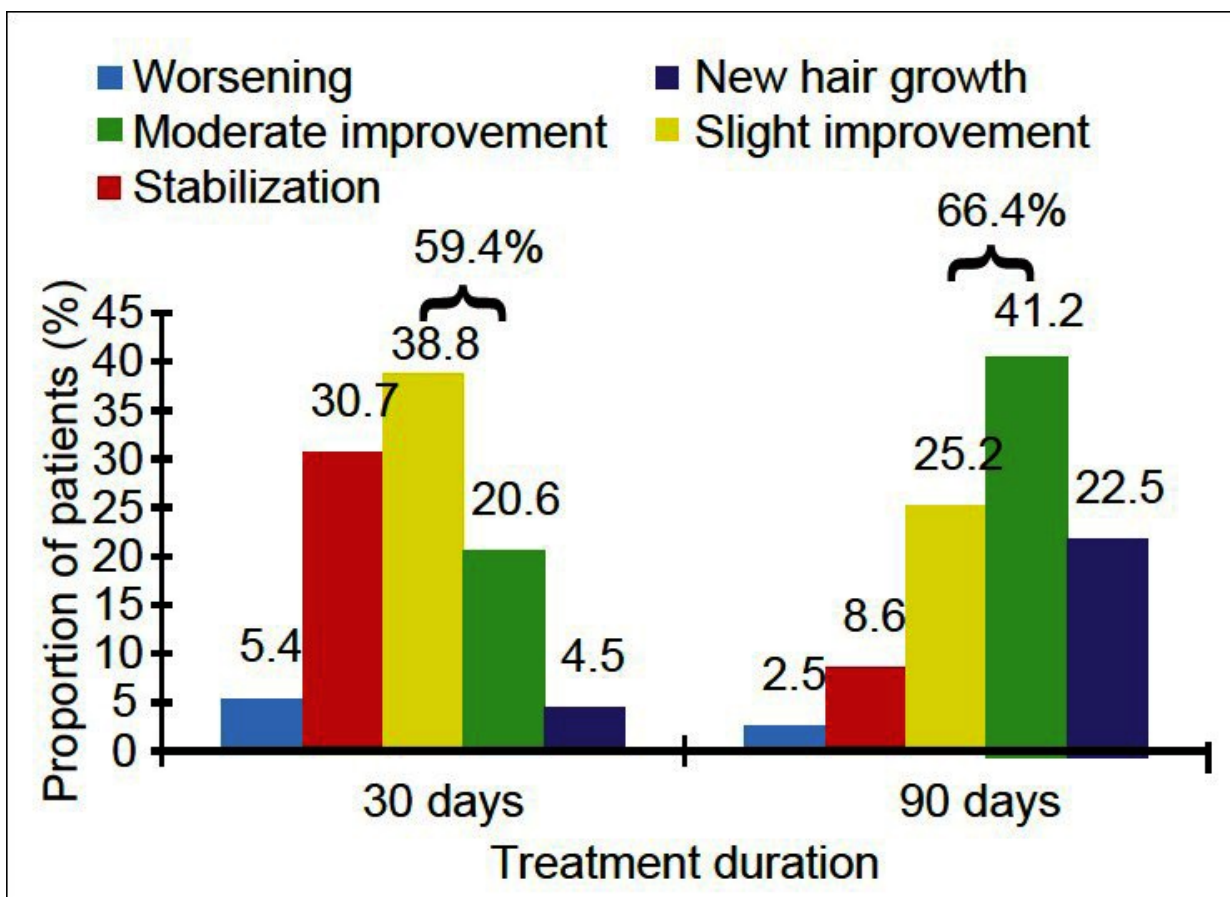
Improvement of hair condition

Figure 4



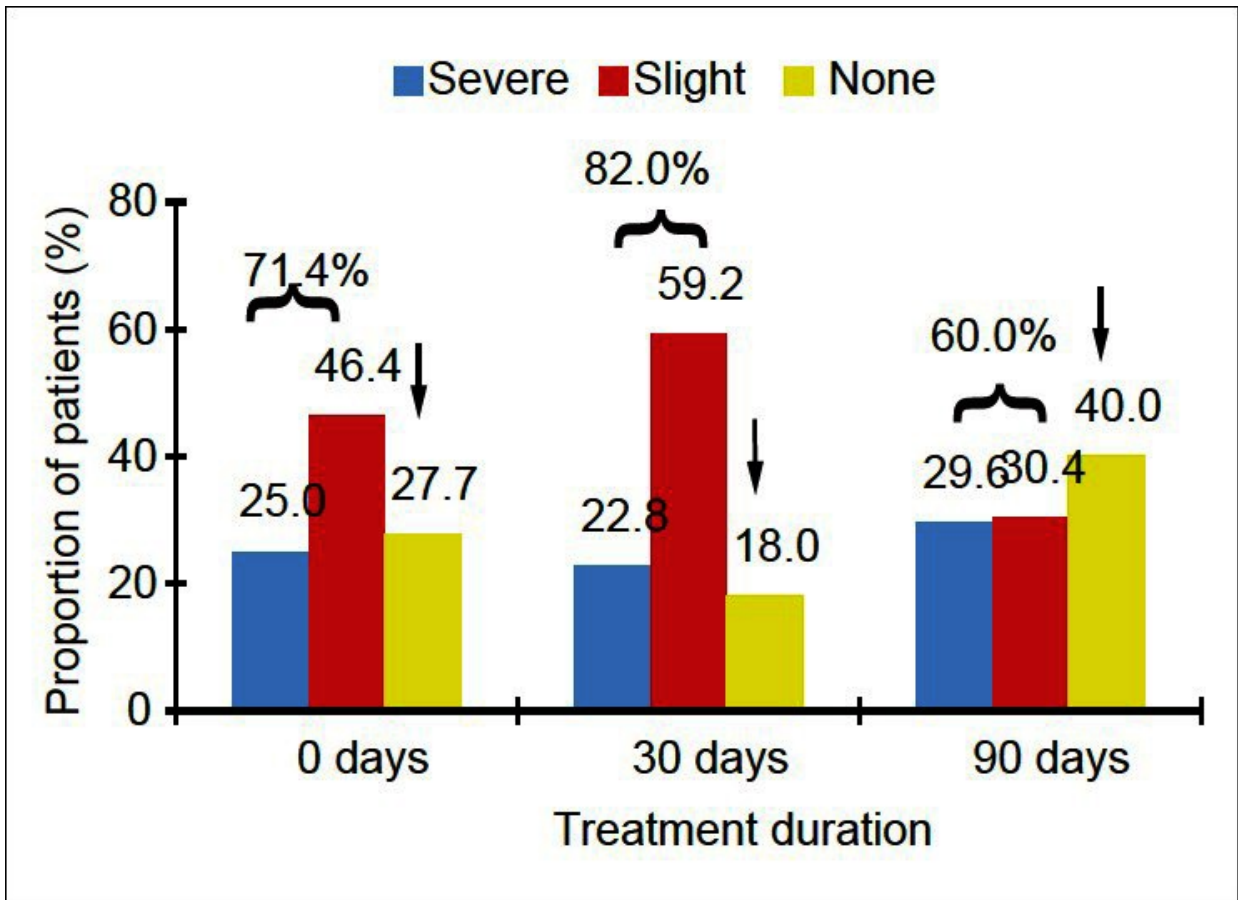
Hair pull test

Figure 5



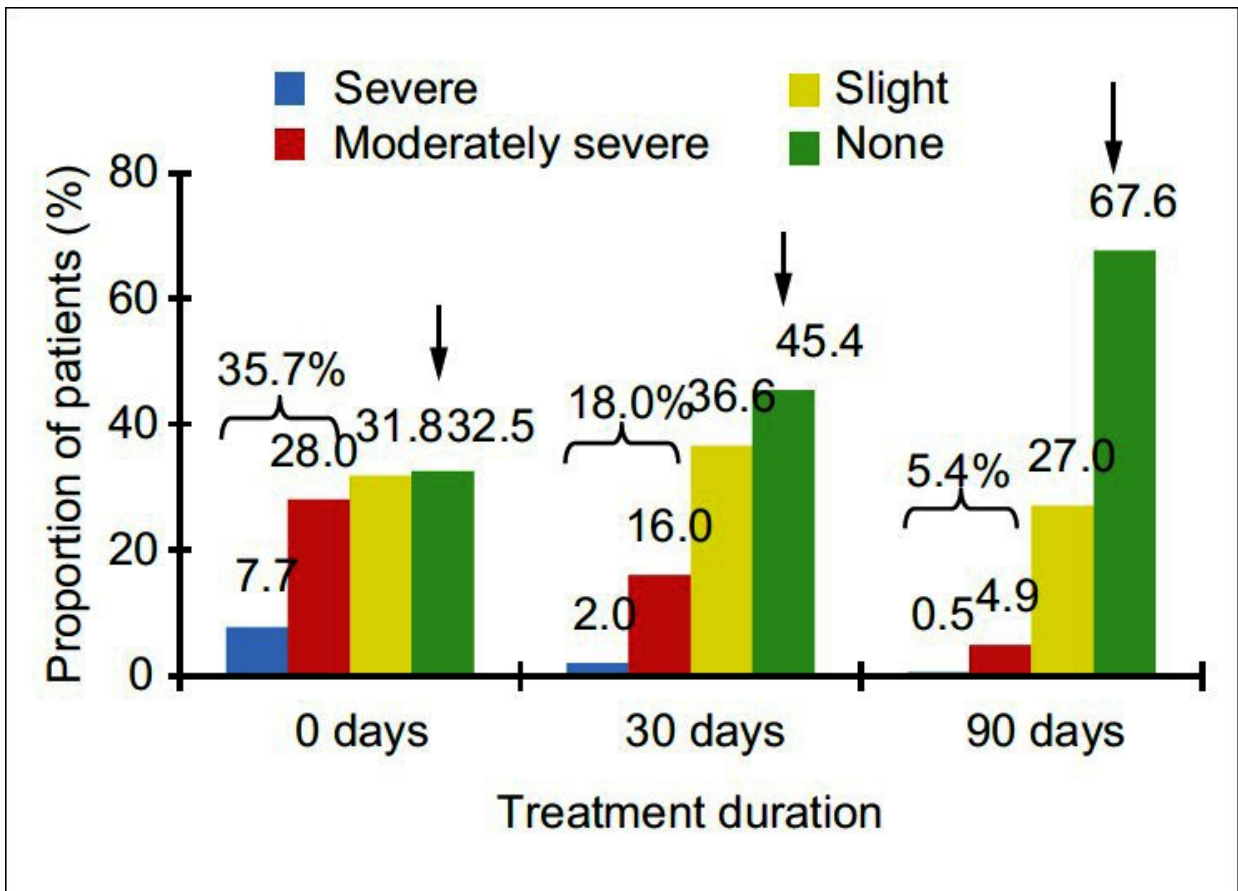
Assessment by medical investigators

Figure 6



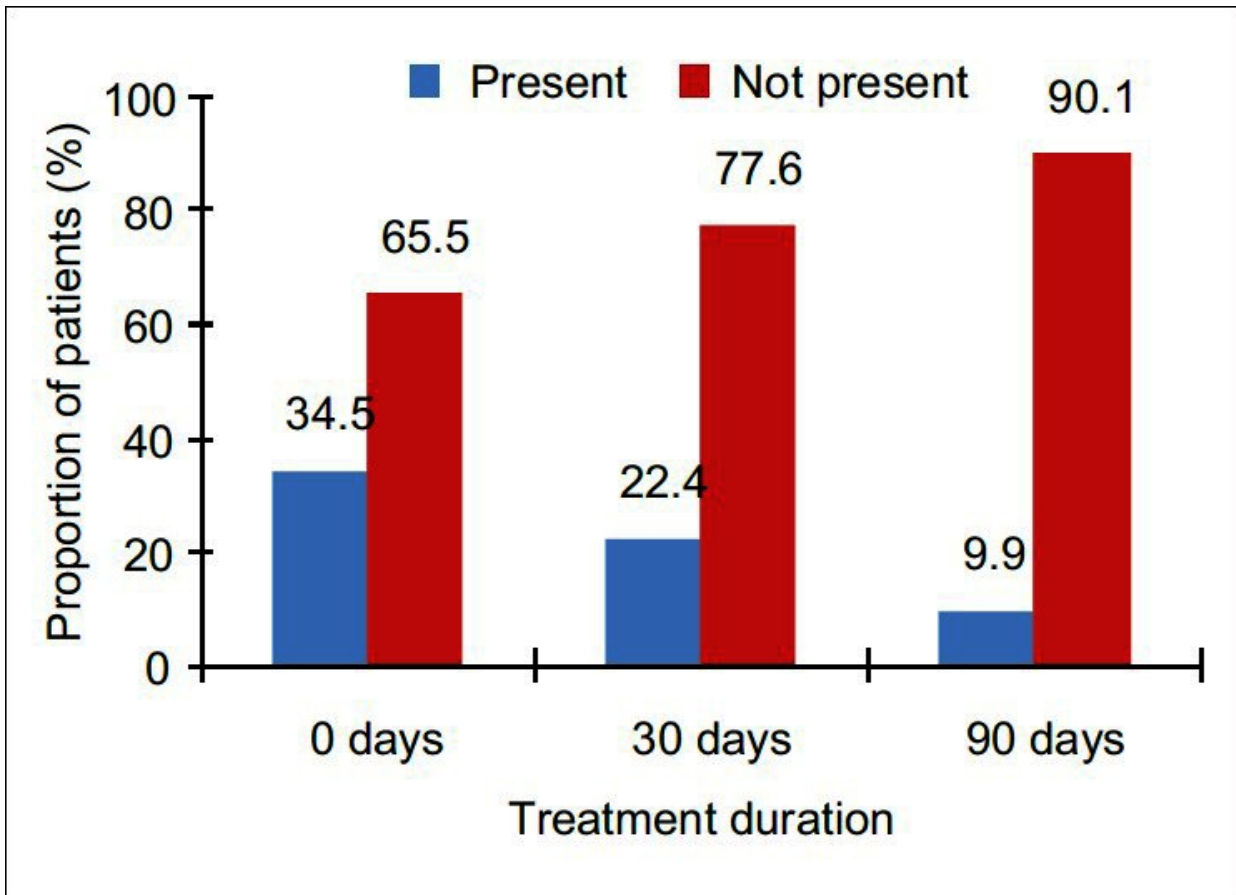
Assessment by patients

Figure 7



Seborrhea

Figure 8



Seborrheic dermatitis

Articles from International Journal of Trichology are provided here courtesy of **Medknow Publications**