

Retinyl Retinoate, a Retinoid Derivative Improves Acne Vulgaris in Double-blind, Vehicle-controlled Clinical Study

Bora Kim¹, Hyunjung Kim², Jin Eun Kim¹, and Seung Hun Lee^{3*}

¹R&D Center of Skin Science and Cosmetics, Enprani Co., Ltd., Incheon, South Korea

²Departments of Dermatology/Atopy and Asthma center & Seoul Medical Research Institute, Seoul Medical Center, Seoul, South Korea

³Department of Dermatology and Human Barrier Research Institute, Yonsei University College of Medicine, Seoul, South Korea,

(Received: July 25th, 2012; July 12th, 2013; July 16th, 2013)

Abstract : Topical retinoids have been an important therapy used in the treatment of acne. However, retinoids often have adverse effects that range from mild to moderate local irritation. Retinyl retinoate is a member of a new generation of well-tolerated synthetic retinoids used as a topical retinoid treatment. To assess retinyl retinoate 0.05% for acne vulgaris therapy, fifteen female patients with mild to moderate facial acne prevalence were included in a double-blind, placebo-controlled, split-face trial for 8 weeks by investigators and measurement of sebum amount. In addition, retinyl retinoate was measured in anti-bacterial efficacy by an agar plate diffusion assay. Retinyl retinoate showed a significant decrease in both inflammatory and non-inflammatory lesions, and in sebum amount at 8 weeks ($P < 0.05$). The application of retinyl retinoate is effective and no local side effects for acne lesions. Retinyl retinoate had somewhat anti-bacterial activity against *Propionibacterium acnes* (*P. acnes*). These results indicate that retinyl retinoate can be used as treatment for mild acne or could potentiate the efficiency of an additive anti-acne agent. Retinyl retinoate is possible to be suggested as a topical anti-acne treatment with excellent tolerance.

Key words: topical retinoid, retinyl retinoate, acne vulgaris, sebum

1. Introduction

Acne vulgaris is a chronic, inflammatory skin disease of the pilosebaceous follicles that mainly affects teenagers, but it is also present in 20% of adults.¹ Acne is generally expected to spontaneously regress during the late teenage or early adult years. Acne has various symptoms including comedones, papules, pustules, nodules, cysts and pilosebaceous inflammation. Acne affects an individual both psychologically and in physical appearance.² The pathophysiology of acne is complex and only partly understood. Multiple factors of pathogenesis are mainly comedogenesis, sebum hyper-excretion, and *Propionibacterium acnes* (*P. acnes*) colonization and inflammation.³ Also, topical retinoids including tretinoin, tazarotene, and adapalene, are widely used to treat mild to moderate acne based on their efficacy in reducing comedogenesis.^{4,5} Retinoids such as retinoic acid, retinol and retinol ester, which are keratolytic agents, have been used to normalize keratinization, as well as for their anti-

inflammatory effect on sebaceous glands.⁶ Isotretinoin is the only medication associated with four pathogenic factors, and is used in the treatment of severe acne by oral or topical administration.⁷ However, retinoid therapy often induces cutaneous dryness, with general irritation including erythema, dryness, itching, and stinging, occur frequently during the early treatment phase. and is responsible for higher skin sensitivity.^{8,9} As acne treatment result in barrier deficiency, it is critical to choose products that have been safe for sensitive skin, in order to minimize irritation and allergenicity.¹⁰ Therefore, we studied a new and suitable retinoid as a long-term medication for maintenance of remission acne. A new retinoid hybrid, retinyl retinoate, with a condensing reaction between retinol and retinoic acid, improved the disadvantages in applying retinol and retinoic acid (Fig 1).¹¹ The side effects of retinoic acid and the instability of retinol were overcome by esterification with retinol and retinoic acid. Retinyl retinoate is a new synthetic retinoid that may be used potentially as a cosmeceutical ingredient in the prevention and improvement of skin wrinkles due to its excellent stability, mildness and higher efficacy in the skin.¹² In this study, an emulsion formulation containing retinyl retinoate 0.05% was therapeutically investigated for acne.

*Corresponding author

Tel: +82-2-2019-3361; Fax: +82-2-3463-6136

e-mail: ydshderm@yuhs.ac (Seung Hun Lee)

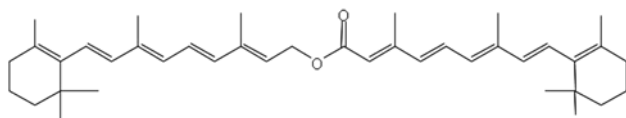


Figure 1. Structure of retinyl retinoate.

2. Materials and Methods

2.1 Patients and Study Design

The severity of acne was graded by visual examination using the Korean Acne Grading System (KAGS, grade 1 ~ 6, Table 1) proposed by the consensus conference in 2004.¹³ Fifteen Korea women, who have facial acne of grade 1 ~ 3, with less than 5 inflammatory lesions (nodules) and mild to moderate facial acne vulgaris, were included in this study at baseline, 2, 4 and 8 weeks. Study design was a double-blind, placebo-controlled, split-face clinical trial. A pea-sized amount of each of the two test products, with vehicle emulsion and 0.05% retinyl retinoate emulsion, was applied once-daily to one half of the face, respectively, every day for 8 weeks. Exclusion criteria for patient subjects were: 1) a facial procedure (e.g. chemical or laser peel) 4 weeks before or during the study, 2) the use of any investigational therapy or topical anti-acne medications and/or systemic corticosteroids 8 weeks and/or systemic retinoids 4 weeks before the start of our study, 3) pregnancy, 4) lactation or nursing.

2.2 Preparation

Placebo emulsion formulation contained: water, EDTA-2Na, propylene glycol, cetearyl olivate/sorbitan, olivate, ethanol, PEG-12 dimethicone, and PEG-60 hydrogenated castor oil. Retinyl retinoate 0.05% emulsion was prepared with same base formulation of placebo emulsion.

2.3 Efficacy Assessments

Efficacy was assessed by a KAGS grade the lesion counting grading system, inflammatory, non-inflammatory, total lesions and safety evaluation by three dermatologists.

Table 1. Korean acne grading system

Grade 1	papules ≤ 10
Grade 2	papules 11~30
Grade 3	papules ≥ 31, nodules ≤ 10
Grade 4	nodules 11-20, ± mild ong oing scars
Grade 5	nodules 21-30, ± moderate ong oing scars
Grade 6	nodules ≥ 31, ± severe ong oing scars, ± sinus tracts

2.4 Measurement of Facial Sebum Secretion

The measurement of facial sebum secretion was performed with the Sebumeter® SM 810 PC (Courage and Khazaka, Cologne, Germany) to examine effect correlations of sebum amount and acne. This device measures the amount of sebum per unit area ($\mu\text{g}/\text{cm}^2$) by using a special sebum absorption tape. The three following areas were measured: forehead (mid-glabella), cheek (the prominent area of the left zygomata), chin (mental prominence).

2.5 Anti-bacterial Activity Assay

Propionibacterium acnes (KCCM 41747) was cultured on Schaedler broth (Becton, Dickinson and Company, Franklin Lakes, NJ, U.S.A.) under anaerobic conditions using the Gas-Pak™ EZ anaerobic container system (Becton, Dickinson and Company) at 37°C. A single colony was inoculated and cultured for 2 ~ 3 days. The culture was diluted 1:50 and cultured until $\text{OD}_{550} = 0.5$. Top agar was added with diluents, then bottom agar mixed with Schaedler broth and 1.5% agar was poured. Trans-retinoic acid, 13-cis retinoic acid, retinaldehyde, retinol (Sigma Chemical Co, St Louis, MO, U.S.A.) and retinyl retinoate were dissolved in DMSO or ethanol. After the agar plate was hardened, retinoids were separately loaded on 6 mm paper discs. After incubation, diameters of clear zone were measured.

2.6 Statistical Analysis

Statistical analysis was performed using the two-tailed student t-test with a significance value of 0.05.

3. Results

3.1 Efficacy Assessment

Fig 2 shows that the mean acne grades of the retinyl retinoate treatment group generally decreased by assessment using KAGS after 4 and 8 weeks. In comparison with the baseline, acne is significantly improved at 4 weeks ($p = 0.04$) and at 8 weeks ($p = 0.013$). The retinyl retinoate treatment improved total acne grading and the numbers of inflammatory and non-inflammatory acne lesions overall. In Table 2, the treatment group showed significant improvement in non-inflammatory and inflammatory lesions after 8 weeks ($p = 0.008, 0.015$, respectively). However, the placebo group did not show statistical significance, although there was a change in improvement ($p = 0.186, 0.19$, respectively) after 8 weeks acne. Percent change of improvement in placebo group is assumed by systemic effect in split-face clinical trial design (Fig 3). Numbers of lesion of both placebo and treat group at baseline did not show significant difference ($p > 0.1$), namely, it means that both acne

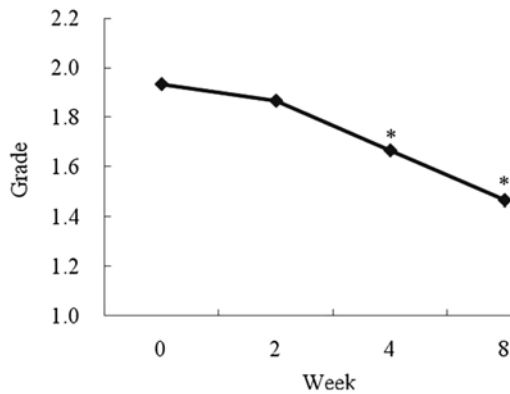


Figure 2. Acne grading based on the KAGS, by retinyl retinoate 0.05% treatment.

facial skin were uniform in split-face clinical trial design. The retinyl retinoate-treated group versus placebo group showed an improvement in total (38.58% vs. 26.47%), inflammatory (43.62% vs. 35.14%) and non-inflammatory (33.98% vs. 19.79%) lesion counts after 8 weeks. In all measurement periods, acne lesions in the retinyl retinoate group were more

improved than those in the placebo group (Fig 3). In safety evaluation, all patients in all of the treatment groups had no adverse symptoms such as erythema, desquamated facial skin, edema, scaling, itching, stinging, burning, tightness and/or prickling sensations. Emulsion containing retinyl retinoate was safe and did not lead to allergic contact dermatitis or irritant contact dermatitis. Retinyl retinoate 0.05% was effective and well tolerated for acne vulgaris for 8 weeks.

3.2 Measurement of Facial Sebum Secretion

To examine the correlation of acne and regional differences of facial sebum, sebum measurements were conducted simultaneously. Amount of sebum in the retinyl retinoate-treated group was significantly reduced on only the forehead when compared with baseline ($p = 0.033$) at 8 weeks (Table 3). Sebum amounts of both placebo and treat group at baseline did not show dramatic significant difference along of presumption of systemic effect and fluctuation of skin sebum change (data not shown). Retinyl retinoate was effective to sebum reduction on a high sebum-secreting T-zone (forehead) not significant effect on a low sebum-secreting U-zone (cheeks, chin).

Table 2. Comparison of lesion numbers in each group.

Measures	Week	Non-Inflammatory Lesions		Inflammatory Lesions		Total Lesions	
		retinyl retinoate	placebo	retinyl retinoate	placebo	retinyl retinoate	placebo
Numbers of lesion	0	7.36	6.86	6.71	5.29	14.07	12.14
	2	6.07	6.29	5.00	5.36	11.07	11.64
	4	4.79	5.57	3.21	3.57	8.00	9.14
	8	4.86 *	5.50	3.79 **	3.43	8.64	8.93

* $p < 0.05$, ** $p < 0.01$

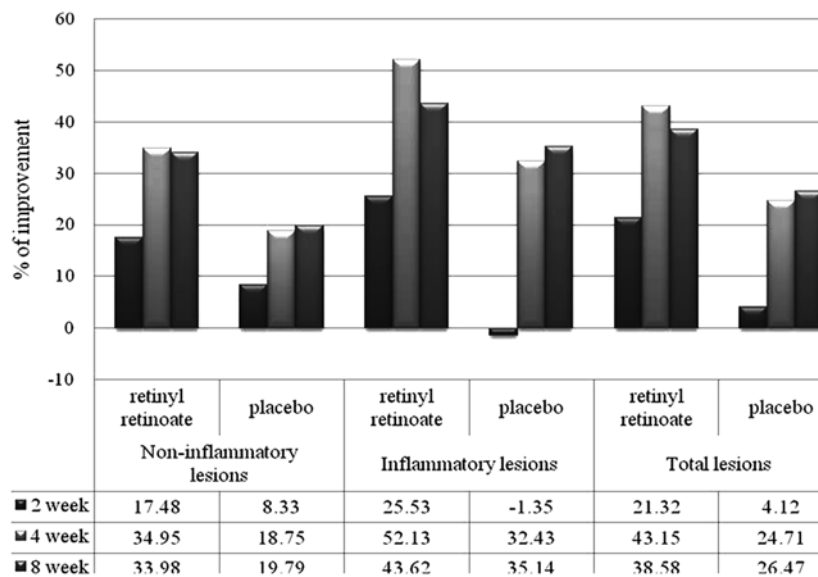


Figure 3. Comparison of % change in the improvement of acne lesions.

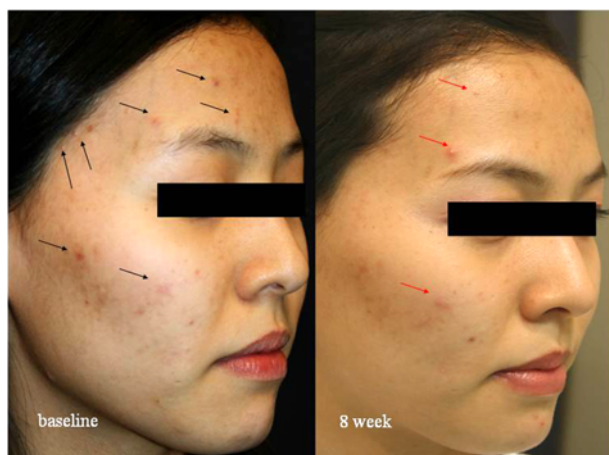Table 3. Comparison of sebum amount and % change of sebum reduction in facial skin.

Measures	Week	Retinyl Retinoate				Placebo			
		forehead	cheek	chin	total	forehead	cheek	chin	total
Sebum ($\mu\text{g}/\text{cm}^2$)	0	104.86	102.50	77.29	284.64	104.07	106.64	76.43	287.14
	2	90.07	73.86	54.29	218.21	96.36	65.14	41.36	202.86
	4	84.36	85.36	71.57	241.29	83.86	85.93	66.29	236.07
	8	76.36*	62.21	54.57	193.14	83.29	65.29	44.71	193.29
% Sebum reduction	2	14.10	27.94	29.76	23.34	7.41	38.91	45.89	29.35
	4	19.55	16.72	7.39	15.23	19.42	19.42	13.27	17.79
	8	27.18	39.30	29.39	32.15	19.97	38.78	41.50	32.69

* $p < 0.05$ **Table 4.** Inhibitory effect of retinoids on *Propionibacterium acnes*.

Concentration 20 mM	Retinol	Retinaldehyde	Retinyl retinoate	13-cis-Retinoic acid	Retinoic acid
cm (diameter)	1.6	1.4	1.0	-	-

: no effect

**Figure 4.** Representative subject from the group treated with 0.05% retinyl retinoate at baseline and 8 weeks.

3.3 Anti-bacterial Activity Assay

To assess retinyl retinoate for anti-bacterial activity, we measured by culture of *P. acnes*. In the comparative results of anti-bacterial direct effects, retinoids showed somewhat different activities. Retinyl retinoate appeared to have little effect (Table 4), and 13-cis-retinoic acid and retinoic acid had no effect on anti-*P. acnes* activity. Therefore, retinol, retinaldehyde and retinyl retinoate may possibly have an effect on *P. acnes* reduction.

4. Discussion

Topical retinoids such as tretinoin are widely used to treat acne vulgaris based on effectiveness in reducing and inhibiting comedogenesis.¹⁴ In our previous reports, retinyl retinoate has many advantages which have better chemical stability, reduced

skin irritant properties and higher skin regeneration activity than the previous retinol or retinoic acid.^{11,22} The 0.06% retinyl retinoate cream for 3 months significantly showed decreased depth and area of wrinkles in comparison with 0.075% retinol cream in clinical trial.²³ These results represent that retinyl retinoate has a stronger therapeutic effect in comparison with retinol. Thus, we expect that retinyl retinoate has retinoid-like physiology in acne vulgaris treatment. In this study, retinyl retinoate effectively decrease inflammatory, and non-inflammatory lesions count in mild to moderate acne patients (Fig 2, Table 2). So, topical retinoids inhibit the formation of microcomedos, thus preventing the formation of mature comedones.⁴ The comedolytic action of retinoids is characterized by their ability to normalize hyperkeratinization, which, in turn, prevents the formation of microcomedos, the precursors to comedones and inflammatory lesions.¹⁵ This may reduce inflammatory lesions. Therefore, retinoids have many functions that directly affect the four major pathogenic steps in the acne formation process. Presently, tretinoin has been used in concentrations of 0.01 ~ 0.1% and combinations of topical antibiotics and retinoid have been used as treatments.^{16, 17} However, due to cutaneous irritation, retinoids like tretinoin have a limited use in the long-term treatment as a medicine. Although retinol was developed to reduce such side effects, it is photo-unstable and has a lower efficacy than other retinoids.¹⁸ Therefore, we developed a new retinoid hybrid, retinyl retinoate which was improved the disadvantages in applying retinol and retinoic acid as well-tolerated and effective topical retinoid. As acne prevalent people have a need to use own cosmetics which are suitable to acne skin type along with medicine. Because acne prevalent patients want to use skin care products, development of

cosmetics ingredient for acne skin are very important. Retinyl retinoate may have similar activity to retinoic acid for acne as well as sebum reduction (Table 3) and anti-bacterial effect (Table 4), at a 0.05% low concentration for a relatively short term of 8 weeks even though small number of patients. Retinoids have controversy on reducing sebum production, the other three factors ; comedogenesis, sebum hyper-excretion, and *Propionibacterium acnes* colonization and inflammation, are closely linked.^{16,19} Regulation of one factor will have a direct or indirect effect on another. *Propionibacterium acnes* is a Gram-positive anaerobic bacterium that mostly inhabits the pilosebaceous follicles of the skin. However, topical retinoids have no direct impact on *Propionibacterium acnes*.²⁰ Although *P. acnes* is a normal skin flora, it plays a critical role in the growth of inflammatory acne when it proliferates the pilosebaceous unit. Retinoids restore abnormal desquamation by epidermal turnover and detaching corneocytes. This promotes an inhospitable aerobic environment for *P. acnes* and facilitates the penetration of drugs. A direct anti-bacterial efficacy against *P. acnes* has been shown by retinol and retinaldehyde.²¹ Therefore, retinyl retinoate has an indirect and slight inhibitory effect on *P. acnes* too. In our previous report, retinyl retinoate was proved to be induced less skin barrier disruption than retinol, retinoic acid and retinaldehyde, but had retinoid-like activity.¹⁸ Retinyl retinoate has enhanced thermal and photo stability, decreased photosensitivity, and has exhibited low cell toxicity compared with retinol and retinoic acid.¹¹ In this study, all patients in all of the treatment groups had no adverse symptoms on retinyl retinoate treatment. These findings imply that the novel retinoid hybrid, retinyl retinoate, has combined advantages, from both retinol and retinoic acid, and has the potential to represent a effective and new generation of topical retinoid. In connection to our previous data, the retinyl retinoate-treated wrinkles improved compared with wrinkles treated with placebo or as assessed by both investigators and skin replica analysis.¹² In accordance with these results, retinyl retinoate may be conveniently used as an active in cosmetics or additive ingredient in medications to prevent and improve acne. This study is promising for the development of cosmetic products to improve one's physical appearance and relieve associated psychological issues caused by acne vulgaris. These findings indicate that retinyl retinoate can be used as treatment for mild acne or could potentiate the efficiency of an additive anti-acne agent. Retinyl retinoate is suggested as a topical anti-acne treatment with excellent tolerance for the development of cosmetic products to improve one's physical appearance and relieve associated psychological issues caused by acne vulgaris.

Acknowledgements: This study was partly supported by a grant of the Korea Healthcare technology R&D Project, Ministry of Health & Welfare, Republic of Korea (Grant No:103017) and the Ministry of Knowledge Economy (MKE), Korea Institute for Advancement of Technology (KIAT) through the Inter-ER Cooperation Projects.

References

1. CN Collier, JC Harper, WC Cantrell, *et al.*, The prevalence of acne in adults 20 years and older, *J Am Acad Dermatol*, **58**, 56 (2008).
2. B Dréno, Assessing quality of life in patients with acne vulgaris: implications for Treatment, *Am J Clin Dermatol*, **7**, 99 (2006).
3. I Kurokawa, FW Danby, Q Ju, X Wang, *et al.*, New developments in our understanding of acne pathogenesis and treatment, *Exp Dermatol*, **18**, 821 (2009).
4. A Thielitz, MB Abdel-Naser, JW Fluhr, *et al.*, Topical retinoids in acne--an evidence-based overview, *J Dtsch Dermatol Ges*, **6**, 1023 (2008).
5. D Thiboutot, H Gollnick, V Bettoli, *et al.*, New insights into the management of acne: an update from the global alliance to improve outcomes in acne group, *J Am Acad Dermatol*, **60**, S1 (2009).
6. AF Alexis, Clinical considerations on the use of concomitant therapy in the treatment of acne, *J Dermatol Treat*, **19**, 199 (2008).
7. B Amichai, A Shemer, MH Grunwald, Low-dose isotretinoin in the treatment of acne vulgaris, *J Am Acad Dermatol*, **54**, 644 (2006).
8. A Akhavan, S Bershad, Topical acne drugs: review of clinical properties, systemic exposure, and safety, *Am J Clin Dermatol*, **4**, 473 (2003).
9. JW Fluhr, MP Vienne, C Lauze, *et al.*, Tolerance profile of retinol, retinaldehyde and retinoic acid under maximized and long-term clinical conditions, *Dermatol*, **199**, 57 (1999).
10. RL Warner, N Bhagavathula, K Nerusu, *et al.*, MDI 301, a nonirritating retinoid, improves abrasion wound healing in damaged/atrophic skin, *Wound Repair Regen*, **16**, 117 (2008).
11. H Kim, B Kim, H Kim, *et al.*, Synthesis and *in vitro* biological activity of retinyl retinoate, a novel hybrid retinoid derivative, *Bioorg Med Chem*, **16**, 6387 (2008).
12. H Kim, N Kim, S Jung, *et al.*, Improvement in skin wrinkles from the use of photostable retinyl retinoate: a randomized controlled trial, *Br J Dermatol*, **162**, 497 (2010).
13. KJ Sung, YS Rho, EH Choi, *et al.*, Korean acne grading system, *Korean J Dermatol*, **42**, 1241 (2004).
14. HPM Gollnick, A Krautheim, Topical treatment in acne: current status and future aspects, *Dermatol*, **206**, 29 (2003).
15. JM Waller, F Dreher, S Behnam, *et al.*, Keratolytic properties of benzoyl peroxide and retinoic acid resemble salicylic acid in man, *Skin Pharm Physiol*, **19**, 283 (2006).
16. CL Goh, MBY Tang, P Briantais, *et al.*, Adapalene gel 0.1% is better tolerated than tretinoin gel 0.025% among healthy

Efficacy of Retinyl Retinoate for Acne Vulgaris

- volunteers of various ethnic origins, *J Dermatol Treat.* **20**, 282 (2009).
17. J Domínguez, MT Hojyo, JL Celayo, *et al.*, Topical isotretinoin vs. topical retinoic acid in the treatment of acne vulgaris, *Int J Dermatol*, **37**, 54 (1998).
 18. JE Kim, B Kim, H Kim, *et al.*, Retinyl retinoate induces hyaluronan production and less irritation than other retinoids, *J Dermatol*, **37**, 448 (2010).
 19. SW Youn, The role of facial sebum secretion in acne pathogenesis: facts and controversies, *Clin Dermatol*, **28**, 8 (2010).
 20. HH Tan, Antibacterial therapy for acne: a guide to selection and use of systemic agents, *Am J Clin Dermatol*, **4**, 307 (2003).
 21. M Pechère, L Germanier, G Siegenthaler, *et al.*, The antibacterial activity of topical retinoids: the case of retinaldehyde, *Dermatol*, **205**, 153 (2002).
 22. B Kim, JE Kim, H Kim, *et al.*, Co-treatment with retinyl retinoate and a PPAR α agonist reduces retinoid dermatitis., *Int J Dermatol*, **51**(6), 733 (2012)
 23. H Kim, J Koh, J Baek, *et al.*, Retinyl retinoate, a novel hybrid vitamin derivative, improves photoaged skin: a double-blind, randomized-controlled trial, *Skin Res Technol*, **17**, 380 (2011)