



Efficacy and safety of moisturizer containing 5% panthenol, madecassoside, and copper-zinc-manganese versus 0.02% triamcinolone acetonide cream in decreasing adverse reaction and downtime after ablative fractional carbon dioxide laser resurfacing

Aphinut Srituravanit¹, Phubodin Vongtaranavuth^{1,2}, Suparuj Lueangrun^{1,*}

¹ Dermatology department, Chulabhorn international college of medicine, Thammasat university, Pathumtani, Thailand

² Pan Rajdhevee and Lion Supanhongsa foundation, Bangkok, Thailand

*Corresponding author: Tel. +66(0)62-4625142; E-mail address: saoraya180@gmail.com

Keywords: Panthenol, Madecassoside, Copper-Zinc-Manganese, Fractional ablative laser, Wound healing

Introduction

Fractional carbon dioxide (FrCO₂) laser is one of the ablative fractional laser resurfacing (AFR) based on the principle of fractional photothermolysis (FP), by which the 10,600-nm wavelength of the carbon dioxide (CO₂) laser is combined with an FP system. The laser ablates epidermis and heats dermal tissue in the so called microscopic treatment zones (MTZs), consisting of sharply columnar tissue denaturation of about 100 µm diameter surrounded by viable tissue.¹ However, the downtime following this laser procedure is often unavoidable despite being an effective tool for atrophic acne scar treatment.² The downtime includes white frosting, likely to last for 5 to 10 minutes immediately after laser irradiation, followed by moderate to marked erythema and edema, usually persisting for 24 hours. Normally, superficial crusting occurs and re-epithelialization is completed within 5 to 7 days, depending on density and energy of the laser. Whilst, post-inflammatory hyperpigmentation (PIH) can be observed after the slough-off crusts, normally around 1 or 2 weeks following the procedure.²

In a recent study, short-term application of postoperative topical steroid could decrease the risk of this downtime after AFR, yet unfavourably disturbed the wound healing process and possibly increased the risk of postoperative skin infection or acneiform eruption as well.³ In this study, 2/40 subjects with topical steroid treatment for 2 days post-operatively developed acneiform eruption. Thus, we aimed to investigate an alternative treatment modality to improve postoperative FrCO₂ laser downtime so that steroid-treated adverse effects could be avoided by using non-steroidal anti-inflammatory agents.

Alternatively, the moisturizer containing 5% Panthenol, Madecassoside, and Copper-Zinc-Manganese (Cicaplast Baume B5, La Roche-Posay, France) is a multi-purpose soothing balm for normal and sensitive skin irritations. With 3 active-ingredients including Dexpanthenol, Madecassoside, and Copper-Zinc-Manganese, this product can yield various positive effects in wound healing process. Dexpanthenol (an active form of panthenol) is the stable alcoholic analogue of pantothenic acid (vitamin B5), known to improve skin barrier by decreasing transepidermal water loss (TEWL), maintaining skin softness, activating fibroblast proliferation, and providing anti-inflammatory effect.⁴ Madecassoside, the extract from *Centella asiatica*, can induce collagen expression, modulate inflammatory mediators, prevent aging, and inhibit proliferation of keloid fibroblast.^{5, 6} Copper-Zinc-Manganese possesses healing properties and improves skin functions by stimulating the keratinocyte proliferation and fibroblasts migration in the skin.⁷

Moreover, this moisturizer containing anti-inflammatory ingredients has also been identified for its treatment efficacy in various skin conditions, such as atopic dermatitis and irritative dermatitis, and is also well-tolerated for most of the patients.^{8, 9} Postoperatively, the use of this cream following the FrCO₂ laser could be a novel treatment modality to decrease the post-ablative laser downtime by using non-steroidal moisturizer containing anti-inflammatory ingredients.

Methods

Patients: Twenty subjects aged ≥ 18 years with atrophic acne scars on both cheeks for at least 6 months were recruited to this split-face, double-blind, randomized controlled trial. Given verbal and written information, all subjects signed the informed consent forms before enrollment. Exclusion criteria were subjects who were pregnant or lactating, received isotretinoin, or underwent invasive facial procedures within the preceding 3 months, as well as those with skin infections or photosensitive skin, and concomitant treatment to the involved skin areas or a propensity for keloid scarring.

Treatment: Preoperatively, lidocaine 2.5% and prilocaine 2.5% cream (Liprikaine; a eutectic mixture of local anaesthetic, T.Man Pharmaceutical Co., Ltd, Thailand) was applied under occlusion for 40 minutes before performing FrCO₂ laser (eCO₂; Lutronic Co., Ltd, South Korea) on both cheeks by a single physician following these parameters of static mode: 120 μ m beam size, 30 W peak power, 50 mJ pulse energy, 1 mm ablation depth, with 2 passes of 100 spots/cm² density and less than 15% coverage. Besides, no concurrent use of epidermal cooling device was performed during the procedure. No postoperative analgesic treatment was required beyond the application of ice compresses for approximately 15–20 min. No prophylactic antibiotics or antivirals were given to any patients.

Postoperative care: Immediately after the laser irradiation, all subjects were taken high-resolution camera images of their faces in 5 positions, with facial scanning by Antera (Antera 3D®; Miravex Co., Ltd, Dublin, Republic of Ireland) device before allowed for ice compression. Two sides of each patient's face were randomly treated with 2 different post-treatment agents; one side of the face with the experimental cream (moisturizer containing 5% panthenol, madecassoside, and copper-zinc-manganese) twice daily for 7 days, while the other side with 0.02%TA cream twice daily for 7 days. All subjects must use 2 separated cotton-buds for applying each cream to avoid contamination. Moreover, they were instructed to wear a broad-spectrum sunscreen with a sun protection factor of 40, avoid sun exposure or use of any topical preparations on the face during the period of study.

Evaluation: All subjects were evaluated on the experimental day (before and immediately after laser irradiation) and additional 4 follow-up visits including day 3, day 5, day 7, and day 14 after irradiation. The evaluation included questionnaires, facial examination, downtime and side effects reported by subjects, high resolution camera imaging, and facial scanning by the Antera device. The pain related to laser procedure was also recorded as the 0-10 pain score, immediately after the laser irradiation.

The facial examination included overall facial skin, erythema, scaling, crusting, dyspigmentation, PIH, skin texture, pore, acne scar, and other side effects. The questionnaires were also completed for downtime and side effects observed by the subjects. Meanwhile, the photographic images were obtained by using a digital camera (Canon PowerShot G1 X Mark II Digital Camera; Canon Marketing Co., Ltd, Thailand) Canon PowerShot G1X with the same camera settings, lighting, and positioning on every visit. The positioning was comprised of 5 positions; frontal, 45 degree left-lateral and right-lateral, and 90 degree left-lateral and right-lateral. Whereas, the Antera facial scanning was obtained in a bid to evaluate the following parameters; haemoglobin (erythema), melanin, elevations (crusting and scaling), pore, depressions (atrophic scars), skin colour, and skin texture.

Results

Demographic data

Twenty subjects (12 males, 8 females) with the mean \pm SD age of 37.55 \pm 9.41 years (range 26-46) and skin phototype IV were enrolled and completed the study.

Efficacies evaluation using biometric facial scan (Antera 3D)

In the experimental cream treated group, haemoglobin index reached its peak (1.91 \pm 0.17) at day 3 before significantly decreased (1.64 \pm 0.14) at day 14 ($p < 0.001$). Melanin index reached its peak (0.57 \pm 0.06) at day 3 and significantly decreased (0.56 \pm 0.07) at day 14 ($p < 0.05$). Meanwhile, scale reached its peak (9.46 \pm 4.88) immediately after laser treatment, then significantly improved (6.80 \pm 4.27) at day 14 ($p < 0.001$)

Table 1 Improvement of FrCO₂ laser's side effects on the side treated with experimental cream

	Before	After	Day 3	Day 5	Day 7	Day 14	P _{value} *
Atrophic scar	11.26 \pm 8.08	12.53 \pm 8.89	10.46 \pm 7.66	11.19 \pm 8.48	11.99 \pm 9.62	11.93 \pm 8.57	0.164
Hemoglobin	1.56 \pm 0.17	1.82 \pm 0.13	1.91 \pm 0.17	1.72 \pm 0.16	1.65 \pm 0.15	1.64 \pm 0.14	<0.001
Melanin	0.56 \pm 0.07	0.56 \pm 0.05	0.57 \pm 0.06	0.56 \pm 0.06	0.56 \pm 0.06	0.56 \pm 0.07	0.019
Pores	5.91 \pm 3.52	9.18 \pm 4.65	7.29 \pm 4.01	6.12 \pm 3.78	6.17 \pm 3.89	6.47 \pm 4.17	<0.001
scale	5.96 \pm 3.59	9.46 \pm 4.88	7.43 \pm 4.00	6.24 \pm 3.76	5.97 \pm 4.12	6.80 \pm 4.27	<0.001
Texture	25.85 \pm 1.84	28.54 \pm 12.22	25.34 \pm 10.19	26.67 \pm 12.30	27.08 \pm 13.19	26.94 \pm 11.65	0.061

*Friedman Test, Post Hoc: Wilcoxon Signed Ranks Test (P-value<0.003)

Whilst, in the 0.02% TA cream treated group, haemoglobin index reached its peak of 1.89 ± 0.18 at day 3, then significantly decreased (1.60 ± 0.15) at day 14 ($p<0.001$). Melanin index reached its peak of 0.58 ± 0.05 at day 3 and significantly decreased (0.56 ± 0.07) at day 14 ($p < 0.001$). Scale index, reached its peak of 8.82 ± 5.52 immediately after laser treatment before significantly improved (5.81 ± 4.11) at day 14 ($p<0.001$) (Table 2).

Table 2 Improvement of FrCO₂ laser's side effect on the side treated with the 0.02% TA cream

	Before	After	Day 3	Day 5	Day 7	Day 14	P-value*
Atrophic scar	11.75±8.52	11.77±9.59	9.94±7.02	11.07±8.10	10.69±8.21	11.23±8.40	0.177
Hemoglobin	1.53±0.13	1.83±0.15	1.89±0.18	1.67±0.16	1.55±0.31	1.60±0.15	<0.001
Melanin	0.57±0.07	0.56±0.05	0.58±0.05	0.56±0.05	0.56±0.06	0.56±0.07	<0.001
Pores	6.13±4.06	8.55±5.24	6.53±3.38	5.99±3.85	5.67±3.97	5.87±3.91	<0.001
Scale	6.13±3.12	8.82±5.52	6.72±3.33	6.08±3.93	5.72±4.18	5.81±4.11	<0.001
Texture	26.43±11.53	27.58±13.19	24.55±9.09	25.55±10.98	25.07±11.31	25.93±11.16	0.085

*Friedman Test, Post Hoc: Wilcoxon Signed Ranks Test (P-value<0.003)

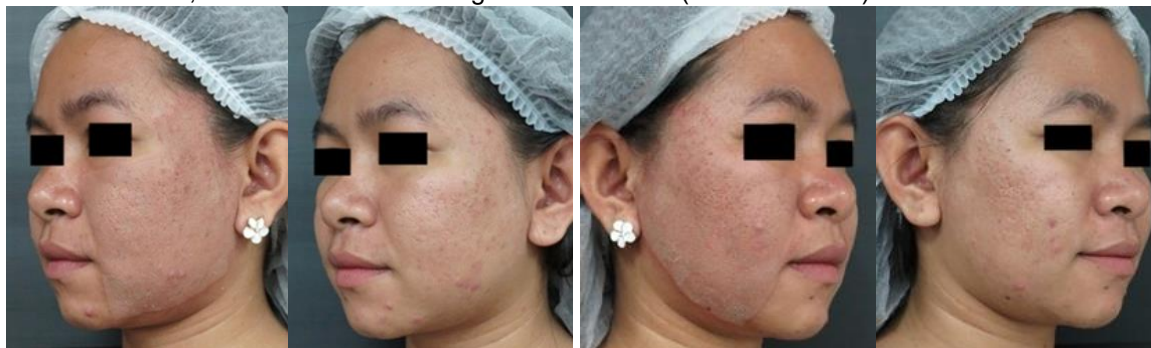


Figure 1 Photograph of the side treated with the experimental cream (left pictures) and 0.02% TA cream (right pictures) immediately after laser treatment and day 14

Interestingly, there was no significant difference in haemoglobin index, melanin index, and scale index between the moisturizer containing 5% panthenol, madecassoside, and copper-zinc-manganese and the 0.02% TA cream at any time point ($p>0.05$). Moreover, no significant difference of skin texture, pores, and atrophic scar volume was observed between the experimental cream and the 0.02% TA cream from baseline to day 14.

The wound healing and downtime evaluated by subjects: There was no significant difference in the improvement of redness, swelling, and burning feeling between the experimental cream and the 0.02% TA cream from baseline to day 14.

Adverse effects: 1 (5.0%) of 20 subjects postoperatively developed acneiform eruption on both sides of the face at the day 3. Additionally, 1 subject (5.0%) complained of mild erythema and tingling feeling on the face of both sides after washing, but not observed by the investigator. While, the pain score after treatment ranged from 4 to 8 with the mean score of 6.95.

Discussion

In our study, the experimental cream containing anti-inflammatory ingredients yielded the efficacy to decrease downtime after FrCO₂ laser irradiation, including erythema, melanin, scale, redness, swelling, and burning feeling, comparable to the 0.02% TA cream. These improved wound healing efficacies and decreased downtime after laser treatment resulted from the active ingredients. Typically, panthenol itself maintains an anti-inflammatory effect crucial to prevent PIH caused by the increasing of melanin distribution and melanin production from various released inflammatory mediators, such as prostaglandin E₂, D₂, leukotriene C₄, D₄, and thromboxane-2.¹⁰ Additionally, panthenol also improves skin barrier by decreasing TEWL and maintaining skin softness⁴, consistent with the improved scaling and crusting in our study. In the meantime, madecassoside modulates the inflammatory mediators and stimulates collagen expression.^{5, 6} Finally, copper-zinc-manganese complexes are the trace elements for skin function improvement by regulating keratinocyte proliferation⁷ related to the wound healing process and scale-crust improvement in this study.

A recent study conducted by Manuskiatti et al. in 2015 revealed that short-term application of high potency topical steroid 0.05% Clobetasol propionate for 2 days after treatment could decrease the risk of PIH and other downtimes following AFR.³ However, there were 2/40 subjects developing acneiform eruption on the treated side with high potency steroid. As a consequence, we used low potency topical steroid and moisturizer with anti-inflammatory ingredients to achieve the efficacious results for downtime improvement after AFR and prevention of adverse effects from high potency steroid. However, there was one subject with acneiform eruption development on both sides of the face at the day 3 after laser treatment in our study, possibly the side effect of AFR. Besides, the experimental cream was well tolerated by all subjects.

Hence, the applying of non-steroidal anti-inflammatory moisturizer in our study could be a novel treatment modality to decrease post-ablative downtime and to avoid adverse effects from the steroid, leading to wound healing process improvement. Nevertheless, further study on the long term effect of this product is recommended due to some limitations including small sample size, short period of follow up, and only the study in Asian population with skin phototype IV. Thus, more sample size, more skin color variation, and a longer study period are suggested to obtain more accurate treatment results of this non-steroidal anti-inflammatory moisturizer to improve the wound healing process and decrease the downtime after AFR.

Conclusion

Moisturizer containing 5% panthenol, madecassoside, and copper-zinc-manganese yielded a comparable efficacy to 0.02% TA cream in decreasing adverse reactions and downtime after FrCO₂ laser irradiation. Alternatively, this moisturizer could be a novel treatment modality for the post-ablative laser downtime with the use of non-steroidal anti-inflammatory agents to avoid high potency steroid adverse effects and improve wound healing process.

References

1. Lowell A, Stephen I, Barbara A, Amy S, David J, Klaus W. Fitzpatrick's dermatology in general medicine. Eighth edition. New York: McGraw-Hill; 2012. Chapter 251, Ablative lasers, chemical peels, and dermabrasion; p. 3021-31.
2. Manuskiatti W, Triwongwanat D, Varothai S, Eimpunth S, Wanitphakdeedecha R. Efficacy and safety of a carbon-dioxide ablative fractional resurfacing device for treatment of atrophic acne scars in asians. *J Am Acad Dermatol*. 2010, 63(2):274-83.
3. Cheyasak N, Manuskiatti W, Maneeprasopchoke P, Wanitphakdeedecha R. Topical corticosteroids minimise the risk of postinflammatory hyper-pigmentation after ablative fractional CO₂ laser resurfacing in asians. *Acta Derm Venereol*. 2015, 95(2):201-5.
4. Ebner F, Heller A, Rippke F, Tausch I. Topical use of dexpanthenol in skin disorders. *Am J Clin Dermatol*. 2002, 3(6):427-33.
5. Haftek M, Mac-Mary S, Bitoux MAL, Creidi P, Seité S, Rougier A, et al. Clinical, biometric and structural evaluation of the long-term effects of a topical treatment with ascorbic acid and madecassoside in photoaged human skin. *Exp Dermatol*. 2008, 17(11):946-52.
6. Song J, Dai Y, Bian D, Zhang H, Xu X, Xia Y, et al. Madecassoside induces apoptosis of keloid fibroblasts via a mitochondrial-dependent pathway. *Drug Develop Res*. 2011, 72(4):315-22.
7. Tenaud I, Sainte-Marie I, Jumbou O, Litoux P, Dreno B. In vitro modulation of keratinocyte wound healing integrins by zinc, copper and manganese. *Br J Dermatol*. 1999, 140:26-34.
8. Crickx B, Lacour J, Arsan A, Assathiany R, Seite S, Fayolle C, et al. A french observational study on the management of epidermal wound healing. *EADV*; 2012.
9. Seite S, Rougier A, Zelenkova H. Interest of madecassoside in the treatment of atopic dermatitis lesion: a randomized double-blind, placebo-controlled clinical study. *EADV*; 2012.
10. Davis EC, Callender VD. Postinflammatory hyperpigmentation: a review of the epidemiology, clinical features, and treatment options in skin of color. *J Clin Aesthet Dermatol*. 2010, 3(7):20-31.
11. Eimpunth S, Wanitphadeedecha R, Manuskiatti W. A focused review on acne-induced and aesthetic procedure-related postinflammatory hyperpigmentation in asians. *J Eur Acad Dermatol Venereol*. 2013, 27(s1):7-18.
12. Wanitphakdeedecha R, Phuardchantuk R, Manuskiatti W. The use of sunscreen starting on the first day after ablative fractional skin resurfacing. *J Eur Acad Dermatol Venereol*. 2014, 28(11):1522-8.